

## Sub-millimeter isotropic ocular-dominance mapping at 7T using 3D EPI

N. Petridou<sup>1</sup>, B. M. Harvey<sup>2</sup>, S. O. Dumoulin<sup>2</sup>, S. F. Neggers<sup>3</sup>, T. Gutteling<sup>3</sup>, P. Luijten<sup>1</sup>, and H. Hoogduin<sup>1</sup>

<sup>1</sup>UMC Utrecht, Utrecht, Netherlands, <sup>2</sup>Psychology, Utrecht University, Utrecht, Netherlands, <sup>3</sup>Rudolf Magnus Institute for Neuroscience, UMC Utrecht, Utrecht, Netherlands

### Introduction

The increased contrast and signal to noise at high fields has made it possible to reconstruct the functional organization of small groups of neurons in human cortex with sub-millimeter in-plane (2D) resolution, such as ocular dominance columns (ODC), [1-3]. Despite this success, 2D based imaging techniques necessarily use anisotropic spatial resolution with limited coverage, i.e. only a single or few slices. These limitations restrict the application of these 2D techniques to subjects that have regions of cortex that are relatively flat. Overcoming these methodological limitations would greatly advance the potential of fMRI for detailed mapping of functional domains. Here we investigate the potential of 3D EPI at 7T with sub-millimeter isotropic resolution to map micro-units in the cortex, and validate it on ODCs.

### Methods

Scanning was performed on a 7T Philips scanner using a volume transmit and a 16-channel receive head coil (Nova Medical). Data were acquired using a T2\*w 3D segmented EPI with SENSE factor = 1.3 x 2.3, TR/TE: 50/25ms, flip-angle: 16°, FOV: 120x120 mm<sup>2</sup>, 0.7 mm isotropic resolution, and 43 coronal slices spanning the visual cortex. The volume acquisition time was 9.9s. 3rd order image-based shimming was applied over the volume of interest using an in-house developed algorithm. The subject was secured in place with foam pads under the neck and within the coil. Stimuli were presented via back-projection onto a screen mounted on the head coil that was visible through mirrors. The stimulus consisted of a dartboard pattern (13° of visual angle), where odd and even spokes are moving in opposite directions. The subject wore red/blue glasses and each eye was alternately stimulated by switching the display contrast between red and blue wavelengths every 20 to 40s (8 to 4 cycles per run). The intensity and stimulus contrast to each eye were matched using psychophysical perceptual procedures. Up to five ~6min runs were acquired. Data were analyzed using AFNI (NIMH/NIH) per run, and for all runs combined after co-registration. Runs with large subject motion were discarded. Time courses were high-pass filtered (cutoff: 0.008Hz) and temporally smoothed with 3 point order statistics filter. The stimulus sine/cosine waveforms were used for subsequent regression analysis.

### Results

Figure 1 shows the activation T-maps for 1 subject for 2 separate runs (Fig. 1B,C;  $p < 0.15$  FDR corrected) and for 4 runs combined (Fig. 1D;  $p < 0.05$  FDR corrected). The maps are shown on an axial view for 4 slices corresponding to a relatively flat region on the lower bank of the right calcarine sulcus (Fig. 1A). Part of the left calcarine sulcus is also shown. Maps are overlaid on the corresponding mean time course intensity image. Red and blue colors represent the right and left eye activation respectively. Time courses for the respective conditions are shown in Fig 1E for two neighboring voxels in V1.

### Discussion

Our results show alternating activation patterns in V1, well localized in gray matter, which may relate to the expected differential ocular stimulation and ODC distribution in that region. These patterns appeared consistent between separate runs. Even though preliminary, these results suggest that at 7T, 3D EPI has the sensitivity to detect small signal changes expected from ODCs and offers an avenue for sub-millimeter isotropic mapping not limited by the underlying anatomy.

### References

1)Yacoub E. et al. *NeuroImage* 37:1161–1177, 2007. 2) Menon R., et al *J. Neurophysiol.* 77: 2780–2787, 1997. 3) Cheng K et al, *Neuron* 32; 359–374, 2001.

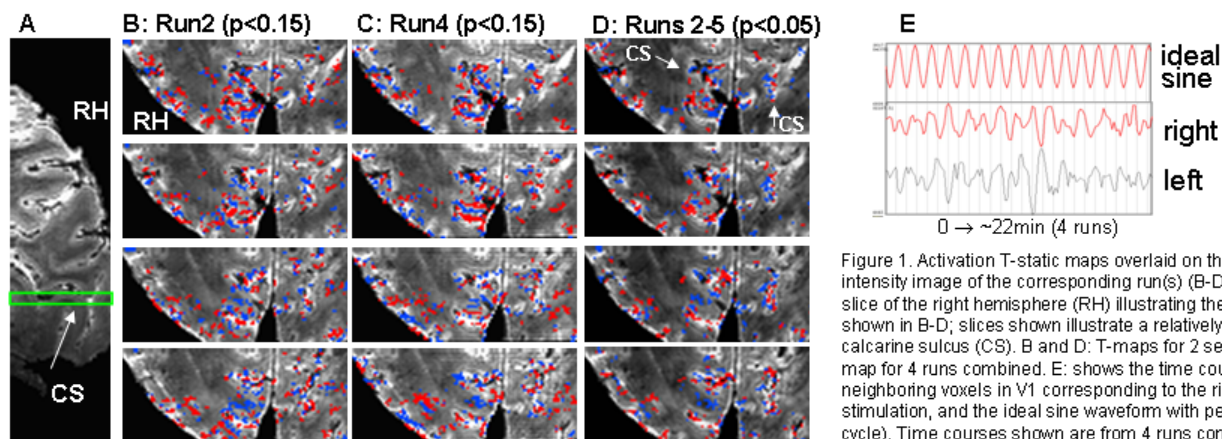


Figure 1. Activation T-static maps overlaid on the mean time course intensity image of the corresponding run(s) (B-D). A: Sagittal view of 1 slice of the right hemisphere (RH) illustrating the position of the slices shown in B-D; slices shown illustrate a relatively flat region of the right calcarine sulcus (CS). B and D: T-maps for 2 separate runs; and D: T-map for 4 runs combined. E: shows the time courses for two neighboring voxels in V1 corresponding to the right or left eye stimulation, and the ideal sine waveform with period of 80s (stimulus cycle). Time courses shown are from 4 runs combined.