

Functional connectivity in resting state CBF mapping in postherpetic neuralgia

J. Liu¹, Y. Zhang², X. Wang¹, M. Du³, and J. Zhang²

¹Department of Radiology, Peking University First Hospital, BeiJing, BeiJing, China, People's Republic of, ²College of Engineering, Peking University, BeiJing, BeiJing, China, People's Republic of, ³Department of Anaesthesiology, Peking University First Hospital, BeiJing, BeiJing, China, People's Republic of

Introduction:

Recent neuroimaging studies have explored the effect of neuropathic pain (NP) on brain networks by measuring the brain activations of those NP patients associated with blood oxygenation level dependent (BOLD). Given the well-known concern with the poor specificity and reproducibility of BOLD fMRI, we investigated the functional connectivity in resting state utilizing cerebral blood flow (CBF) mapping with arterial spin labeling (ASL) sequence [1-4], which provides more spatial specificity and consistency [5]. This study aims to build a default mode of brain function both in patient suffering from postherpetic neuralgia (PHN) and healthy subjects using CBF contrast and then, compare the different patterns between the two groups to illustrate how pain modulates the brain networks.

Materials and Methods :

Ten consecutive patients suffering from PHN (9 males, 1 female; age range=48-78, mean age=55 years) underwent standard MR brain scanning. The duration of pain is longer than 3 months and the score of visual analog scale (VAS) is above 6 points both on the day of the study. Patients didn't accept any kind of therapy for at least one month before imaging. Ten healthy volunteers acted as controls. None of the healthy subjects suffered from any kind of chronic pain. None of them were on medications which may alter brain activity. During the scanning time, all of subjects were instructed to keep their eyes closed, think of nothing and stay awake. Simultaneous acquisition of BOLD and CBF was performed for 8 minutes during resting state.

All MRI experiments were performed on a GE 3T Signa system with a standard head coil. Functional data were acquired using a double readout spiral-out sequence with simultaneous CBF and BOLD acquisition [6]. CBF/BOLD readouts were acquired at TE of 3.1/30 ms covering 10-12 axial slices of the cerebrum and most of the cerebellum. REST2007V1.3_090401, SPM2 and MATLAB were used for data processing. The posterior cingulate cortex (PCC) of right side was selected as a seed region and computed its mean CBF time course. Then, we correlated the mean time course with every pixel to build statistical map for each group. Finally, the results of the two groups were compared and two sample t-test was used to identify regions with statistically significant correlation to the difference of the two groups (cluster corrected $p < 0.01$, contiguous voxels > 10).

Results :

Functional connectivity analyses of resting state using PCC as seed with correlation coefficients bigger than 0.5 in the control group revealed that the areas activated in default mode were accord with those previously reported [7] by measuring BOLD contrast (fig 1), such as bilateral PCC, precuneus, anterior cingulate cortex (ACC) and medial frontal gyrus (MFG) on the opposite side. From functional connectivity comparison between the two groups (fig 2), we found some areas strengthened correlated with the right PCC in patients, comparing with the healthy subjects, such as bilateral anterior cingulate cortex (ACC), the right claustrum, the right insula, bilateral caudate nucleus, the right parietal lobe, the right superior frontal gyrus, the right middle frontal gyrus, the right temporal lobe and the left inside prefrontal lobe. None showed weakened correlation with the right PCC in patient group.

Conclusion :

In conclusion, We first depict a functional network of brain areas that mark the spontaneous component of PHN. This study also showed the potential application of CBF in fMRI research. In this study, the strengthened parts like ACC [8] and insula have a strong relationship with pain. Another strengthened part----inside prefrontal lobe, related to dysmnnesia, which is more common in aged.

References:

- [1] Edelman, R.R., et al. Radiology. 1994; 192(2):513-520.
- [2] Kwong, K.K. et al. Magn Reson Med. 1995;34(6):878-87.
- [3] Kim, S.G. et al. Magn Reson Med. 1995; 34(3): 293-301.
- [4] Yang, Y. et al. Magn Reson Med. 1998;39(5):825-32.
- [5] Tjandra, T. et al. Neuroimage. 2005;27(2): 393-401.
- [6] Wong EC. et al. NMR Biomed, 1997,10: 237-249.
- [7] Friston KJ. Hum Brain Mapp, 1994 2:56-78.
- [8] A. Mobascher, et al. International journal of psychophysiology. 2009(10).

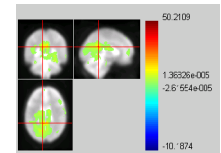


Fig 1 the functional connectivity of resting state in the control subjects.

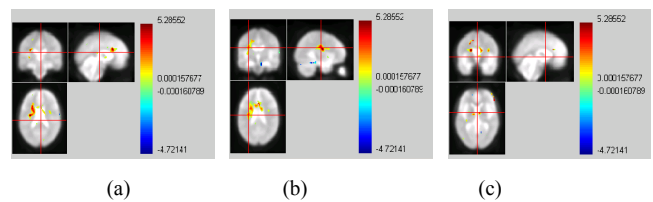


Fig 2 functional connectivity difference between-groups, for patient (a)ACC (b)claustrum (C)caudate nucleus and insula showed strengthened.