

## Direct Visualization and Quantitation of CSF flow in Shunts

N. Alperin<sup>1,2</sup>, S. H. Lee<sup>1</sup>, L. Macedo<sup>3</sup>, D. Rigamonti<sup>4</sup>, and A. Blitz<sup>3</sup>

<sup>1</sup>University of Miami, Miami, FL, United States, <sup>2</sup>Radiology, University of Miami, United States, <sup>3</sup>Radiology, Johns Hopkins, Baltimore, MD, <sup>4</sup>Neurosurgery, Johns Hopkins, Baltimore, MD

### Introduction

Diversion of excessive cerebral spinal fluid (CSF) from hydrocephalic brains by shunting is, in many cases, a life saving procedure. The down side of shunting is high failure rate (40% in the first year, and about 10% annually thereafter). Consequently, about 43% of the estimated 40,000 shunting procedures performed annually in the US alone are for shunt replacement. A study of implanted ventricular shunts in the US found the annual cost of treatment in the year 2000 exceeded one billion dollars [1]. The decision for shunt replacement is often challenging as there is no reliable noninvasive diagnostic test for shunt function. A reliable noninvasive measurement of volumetric flow through shunts may therefore improve the decision for shunt replacement and perhaps reduce unnecessary shunting procedures.

### Methods

Six shunted patients (3M:3F, ages 33 to 83years) underwent MRI brain study on 3T scanners (Siemens Healthcare). The MRI exam included high resolution 3D Constructive Interference Steady State scan to image the path of the shunt and a high temporal and spatial resolution retrospectively gated cine phase contrast scan in a plane perpendicular to the shunt with FOV of 8x8 cm, matrix of 320x320, flip angle of 20 degrees, TR/TE of 16.45/10.5 ms, and VENC of 3 cm/sec. Velocity encoding images were reconstructed for 32 phases during one cardiac cycle. Identification of the shunt lumen pixels was based on detecting cohesive pulsatile CSF flow in connected pixels using cross correlation. Automated lumen identification was obtained using a previously reported pulsatility based segmentation technique [2]. Volumetric flow rate waveform through the shunt was obtained by summation of the velocity values over the shunt lumen pixels. Peak mean velocity, peak mean flow, stroke volume and accumulated flow were calculated. In 4 subjects additional cine phase contrast scan with high and low VENC (70 and 7cm/sec, respectively) were acquired at the level of mid c2 to obtain arterial inflow and cranio-spinal CSF flow waveforms. Systolic onsets of the arterial inflow and the cranio-spinal CSF flow were determined for timing reference for validation of the systolic phase of the shunt CSF flow waveform.

### Results

In 3 of the 6 subjects, pulsatile flow was detected through the shunt. The diagnosis in the cases where no flow was detected was consistent with occluded shunt. Figure 1 shows a CISS image depicting the path of the shunt and the location of the imaging plane used for the cine phase contrast scan (green line). Figure 2 shows the volumetric flow rate waveform (2 cycles). The red and green arrows indicate onsets of arterial and CSF flows, respectively. Figure 3 shows the time integral over one cardiac cycle demonstrating the accumulated CSF volume flowing through the shunt. Peak systolic mean velocity and volumetric flows ranged from 9.6 to 20 mm/sec, and 0.42 to 0.99 mL/min, respectively. The accumulated volume ranged from 2.2 to 6  $\mu$ L over one cardiac cycle. This is equivalent to about 0.14 to 0.35 mL/min, which is within the previously reported range for the supra-tentorial CSF production rate of  $0.30 \pm 0.15$  mL/min, measured by MRI [3].

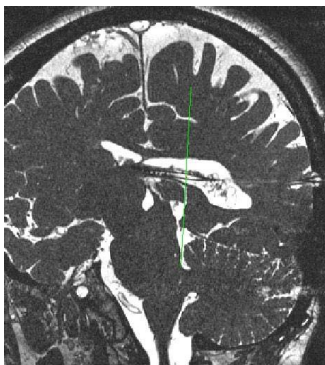

Fig 1. CISS image of the shunt. Green line indicates imaging plane.

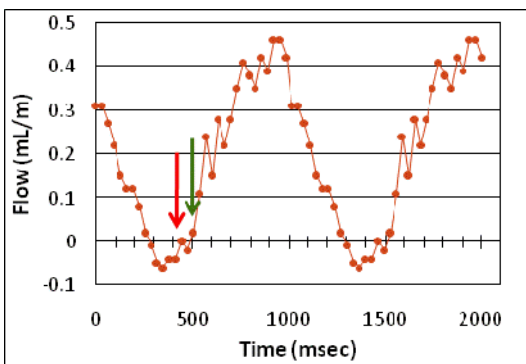


Fig 2. Flow waveform through the shunt (2 cycles). Red and green arrows indicate onsets of arterial and cervical CSF flow

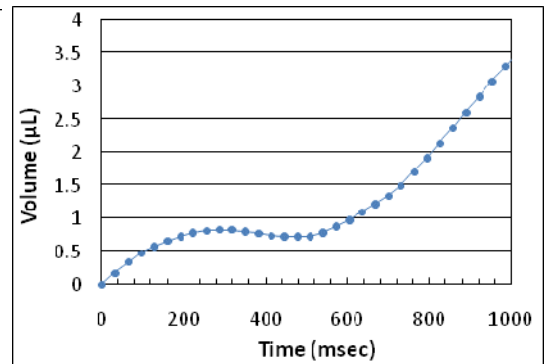


Fig 3. Accumulated CSF volume flowing through the shunt over one cardiac cycle.

### Conclusions

Direct visualization and quantitation of CSF volumetric flow through shunts is feasible with high temporal and spatial resolution cine phase contrast technique and automated detection of cohesive flow in connected pixels. Direct visualization and quantitation of CSF flow through the shunt would provide valuable information on shunt patency and functionality. Phantom studies are underway to estimate the accuracy of the derived accumulated net CSF outflow.

### References

- [1] Patwardhan, R. V. and Nanda, A. Neurosurgery 2005; 56:139-45.
- [2] Alperin N and Lee SH, Magn Reson Med 2003; 49:934-944.
- [3] Huang TY et al. Radiology 2004; 233:603-608.