

# Finding Early Prognostic Marker from 3D <sup>1</sup>H-MRSI and Diffusion Tensor Imaging for Newly-Diagnosed GBM Patients Receiving Radiation, Temozolomide and PKC Inhibitor

I. Park<sup>1,2</sup>, A. Elkhalef<sup>2</sup>, A. Kadambi<sup>2</sup>, I. Khayal<sup>2</sup>, N. Butowski<sup>3</sup>, S. M. Chang<sup>3</sup>, and S. J. Nelson<sup>1,2</sup>

<sup>1</sup>Joint Graduate group in Bioengineering, University of California San Francisco/Berkeley, San Francisco, CA, United States, <sup>2</sup>Surbeck Laboratory of Advanced Imaging, Department of Radiology and Biomedical Imaging, University of California San Francisco, San Francisco, CA, United States, <sup>3</sup>Department of Neurological Surgery, University of California San Francisco, San Francisco, CA, United States

**Introduction:** The dynamic nature of glioblastoma multiforme (GBM), which is characterized by relatively short time-to-progression and survival, emphasizes the need for prognostic tools that can detect significant changes early into treatment and evaluate the likelihood of therapeutic response. The purpose of this study was to use 3D <sup>1</sup>H MR Spectroscopic Imaging (MRSI) and diffusion tensor imaging (DTI) to develop early prognostic markers for GBM patients undergoing radiation, temozolomide and PKC inhibitor.

**Methods:** Twenty-nine patients with newly diagnosed GBM were examined for this study (22M/7F, 27-81 years, 58 median years). All patients received an MR scan prior to treatment, at 1 month and every 2 months thereafter using a 3T MR scanner (GE Healthcare, Milwaukee, WI) with an 8-channel phased array head coil. The imaging protocol included a lactate edited 3D MRSI (TR/TE=1104/144 ms with 1cc nominal resolution, 16x16x16 readout coverage) incorporating a flyback echo planar readout gradient [1] and DTI data acquired using 6 gradient directions in the axial plane (TR/TE=7000/76ms, voxel=0.9x0.9x3mm, b=1000s/mm<sup>2</sup>). Automated algorithms determined maps of the choline-to-NAA index (CNI) and apparent diffusion coefficient (ADC) [2]. ADC values were normalized (nADC) by the median ADC in normal appearing white matter (NAWM). To compute the median ADC within the maximum CNI voxel, the ADC image was resampled to MRSI resolution by averaging values in neighboring voxels. Lactate from 3D <sup>1</sup>H MRSI was normalized (nLac) by the median NAA in NAWM. In order to account for the portion of normal tissue in a voxel, normalized excess choline (exCho) and excess creatine (exCre) were calculated using the following equation:

$$exMet = (Met - NAA \left( \frac{Met}{NAA} \right)_{NAWM}) / Met_{NAWM}$$

where exMet represents either exCho or exCre, and Met, Met<sub>NAWM</sub> and (Met/NAA)<sub>NAWM</sub> correspond to Cho or Cre in a voxel, Cho or Cre in NAWM and Cho over NAA or Cre over NAA ratio in NAWM, respectively. All parameters were analyzed within T2ALL, which contained the entire anatomic abnormality including contrast-enhancing lesion (CEL) and FLAIR abnormality. Patients were classified into two groups based on time-to-radiological-progression (TTP): early progressor (EP), who progressed between 1-6 months (N=19) and late progressor (LP), who progressed after 6 month (N=10). Nonparametric comparisons were made between groups at each scan interval and across time points for the same group (Wilcoxon Ranked-Sum/Signed-Rank tests).

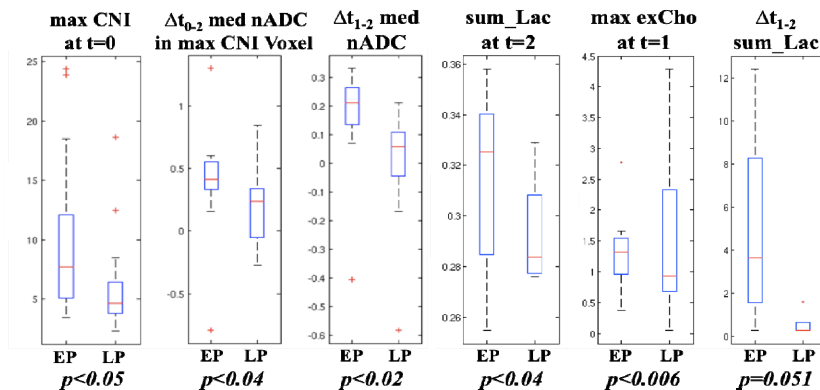


Figure 1: Spectroscopic and diffusion parameters that are predictive of time-to-radiological-progression for patients with GBM. All parameters were analyzed within T2ALL.

**Results:** Figure 1 summarizes the results. At the baseline, the maximum and median CNI value provided the best classification of early progression ( $p < .05$ ). At the 1 month scan, the maximum and median CNI ( $p < .01$  and  $p = .056$ , respectively) and the maximum and median exCho ( $p < .006$  and  $p < .05$ , respectively) were most predictive of advancing disease. At the 2 month scan, the summation of normalized lactate peaks (sum\_Lac) were significant indicator of early progression ( $p < .04$ ). In terms of the change in parameters across time points, the change in median nADC in the maximum CNI voxel from the baseline to 1 month and in T2ALL from the baseline to 2 month and from 1 month to 2 month were statistically significant between EP and LP. The change in sum\_Lac from the baseline to 2 month showed strong trend toward significance between the two groups ( $p = .051$ ). The exCre was not significant at any time points. In addition, neither CEL nor T2ALL volume were predictive of TTP at baseline or 1 month (Fig 2).

**Conclusions:** Conventional anatomical imaging parameters could not distinguish between progression groups at baseline or 1 month. Parameters derived from MRSI and DTI provided information at baseline and early follow-up examinations that may be valuable in predicting the time-to-progression for patients with GBM.

**References:** [1] Park et al., *Proc. ISMRM, 15th Annual Meeting, 2007*. p 775. [2] Nelson SJ, et al., *Magn Reson Med*.2001;46: 228-239.

**Acknowledgement:** This research was supported by NIH RO1 CA127612 and PO1 CA11816.

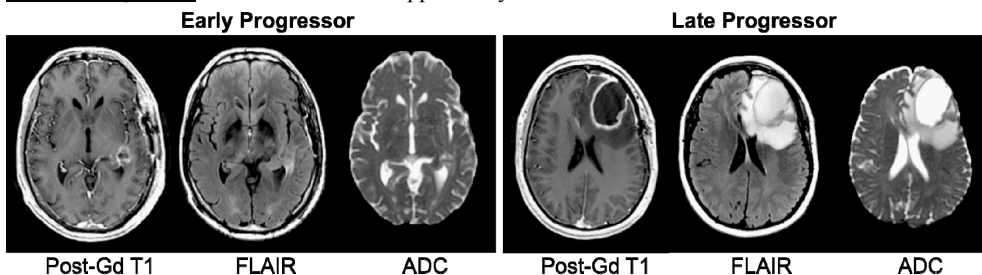


Figure 2: An example of baseline images between an early progressor (EP) and a late progressor (LP). The EP patient progressed at 82 days and had contrast-enhancing lesion (CEL) volume of 2.8 cc and maximum/median CNI of 9.6/4.8. The LP patient progressed at 242 days and had CEL volume of 19.0 cc and maximum/median CNI of 2.4/2.2.