

DETERMINATION OF STRUCTURAL DIFFERENCES BETWEEN GLIOBLASTOMAS AND METASTASES BY DIFFUSION KURTOSIS IMAGING

P. Raab^{1,2}, E. Hattingen², K. Franz³, F. E. Zanella², and H. Lanfermann^{1,2}

¹Neuroradiology, Hannover Medical School, Hannover, Germany, ²Neuroradiology, JW Goethe University, Frankfurt/Main, Germany, ³Neurosurgery, JW Goethe University, Frankfurt/Main, Germany

Introduction

Pathologic changes of tissue structure of the brain parenchyma are difficult to measure by conventional magnetic resonance imaging (MRI) techniques. The recently developed technique of diffusion kurtosis imaging (DKI) (1-3) has shown its potency for tissue characterization (4,5). This method investigates the non-Gaussian diffusion pattern of water and can be interpreted as a measure of tissue structure complexity. Solitary brain neoplasms in patients are often glioblastomas (GBM) or metastatic tumors (Met). The differentiation based on conventional MR imaging (MRI) can be challenging, especially in cases with primary glioblastomas. The purpose of this study was to evaluate whether the DKI technique is able to detect differences between glioblastoma and metastatic neoplastic tissue within the tumor and in the surrounding area.

Methods

In this IRB approved and patient consented study we evaluated 9 patients with solitary metastatic disease and 14 patients with glioblastomas. Scans were performed using a 3T scanner, we compared diffusional measures of mean (MK), radial and axial kurtosis (radK, axK); mean (MD), radial and axial diffusivity (radD, axD) and fractional anisotropy (FA) data for the solid tumor core based on T2-weighted images as well as mean kurtosis, mean diffusivity and fractional anisotropy for the near surrounding tissue. A dual spin echo sequence (TR 2300ms, TE 109ms, parallel imaging factor 2, two averages, 4mm slice thickness, Matrix 128², scanning time 11min 57sec) was used. An anatomic T2 scan for reference reasons was acquired with identical slice positioning. The t-test was used to test for group differences. In a subgroup analysis we separated the glioblastomas into solitary neoplasms mimicking metastasis (n=9) and diffusively infiltrating tumors (n=5) and compared those with the data of metastatic neoplasms. The tumor data were compared to normal appearing contralateral white matter.

Results

In the primary analysis we found significant differences between GBM and Met for FA (p<0.041), MK (p<0.046), axK (p<0.034) of the tumor tissue and mean kurtosis in the surrounding tissue (p<0.032) (Fig. 1). In the subgroup analysis between Met and Met-mimicking GBM there were significant differences found for FA of the tumor tissue (p<0.047) while there was no difference in the surrounding tissue.

Conclusions

Diffusional kurtosis imaging can be used to characterize tissue differences between glioblastomas and metastatic neoplasms of the brain.

Glioblastomas tend to have higher FA values, which might be caused by the more infiltrative nature of GBM. Metastases are characterized by higher mean and axial kurtosis values, indicating an increased tissue structure complexity compared to glioblastomas.

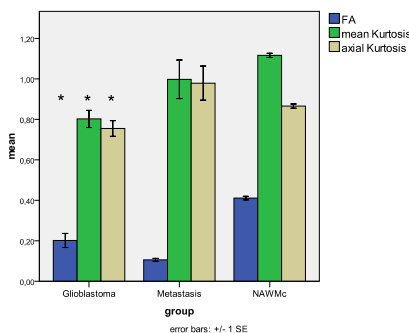


Figure 1. Diagram showing the significant differences (“**”) between the glioblastoma and metastases groups. For comparison the mean data for normal appearing white matter of the contralateral side (NAWMc) are shown as well.

1. Jensen JH, Helpert JA. Quantifying Non-Gaussian Water Diffusion by Means of Pulsed-Field-Gradient MRI; 2003; Toronto, Canada. p 2154.
2. Jensen JH, Helpert JA, Ramani A, Lu H, Kaczynski K. Diffusional kurtosis imaging: the quantification of non-gaussian water diffusion by means of magnetic resonance imaging. *Magn Reson Med* 2005;53(6):1432-1440.
3. Lu H, Jensen JH, Ramani A, Helpert JA. Three-dimensional characterization of non-gaussian water diffusion in humans using diffusion kurtosis imaging. *NMR Biomed* 2006;19(2):236-247.
4. Falangola MF, Jensen JH, Babb JS, Hu C, Castellanos FX, Di Martino A, Ferris SH, Helpert JA. Age-related non-Gaussian diffusion patterns in the prefrontal brain. *J Magn Reson Imaging* 2008;28(6):1345-1350.
5. Raab P, Hattingen E, Franz K, Zanella F, Lanfermann H. Diffusional kurtosis imaging of cerebral gliomas – analysis of microstructural differences. *Radiology* (in Press) 2009.

Acknowledgement: We thank Jens Jensen, PhD (NYU, USA), Hanzhang Lu, PhD (UT Southwestern Medical Center, USA), for their technical help and Ali Tabesh, PhD (NYU, USA), for his help with data processing.