

Assessment of Invasion and Recurrence in Glioblastoma Multiforme using Diffusion Weighted MRI Edge Characteristics of Contrast Enhancing Tumor

P. S. LaViolette^{1,2}, B. M. Ellingson^{2,3}, J. M. Connelly^{2,4}, M. G. Malkin^{2,4}, S. D. Rand^{2,3}, and K. M. Schmainda^{1,2}

¹Biophysics, Medical College of Wisconsin, Milwaukee, WI, United States, ²Translational Brain Tumor Program, Medical College of Wisconsin, Milwaukee, WI, United States, ³Radiology, Medical College of Wisconsin, Milwaukee, WI, United States, ⁴Neurology, Medical College of Wisconsin, Milwaukee, WI, United States

INTRODUCTION

The degree of tumor invasion is difficult to assess in many types of brain cancer and is thought to be the primary reason for failure of surgical excision and focal radiation therapy. Diffusion weighted imaging (DWI) measures the movement of water molecules and has been described as an indirect proxy of cellular density. Based on a recent report (1), we hypothesized that diffusion characteristics at the edge of contrast-enhanced tumor may be useful for quantifying the degree of tumor invasion and potentially predict locations of radiographic recurrence.

METHODS

Four patients who underwent clinical MRI studies, which included DWI, were analyzed for this study. Patients all presented with pathologically confirmed WHO Grade 4 Glioblastoma Multiforme (GBM). Patients underwent sub-total resections, and their standard of care included radiation treatment and chemotherapy. Patients were chosen because of eventual tumor recurrence defined by new contrast enhancement on MRI that did not resolve. MRI data gathered the date prior to recurrence (T_1) (43, 26, 96 and 28 days prior) were compared to that acquired at recurrence (T_2). A region of interest (ROI) was drawn encompassing contrast-enhancing tumor at both time points (Figure 1) creating two separate regions of interest. A surface model was wrapped around the T_1 ROI and partially smoothed, creating a "balloon model". This surface was then inflated isotropically in 1mm steps, and ADC values were sampled at each inflation step. The T_2 ROI was also sampled onto the balloon model at each inflation step, allowing the separation of profile steps into "recurring" and "non-recurring" types. Resulting profiles were then thresholded to exclude CSF valued ADC voxels, averaged and plotted.

RESULTS

The balloon model profiles, when categorized into recurring and non-recurring tissue, show striking evidence indicative of tumor invasion at the time point prior to contrast enhancement (Figure 2). The profiles show heightened ADC straddling troughs of decreased ADC. This potentially can be explained by heightened edema surrounding an invasive "tumor cell bed". In patients 1 and 3 the area of decreased ADC (tumor bed) appears to lie between 3-5mm beyond the edge of the initial contrast enhancement, while patient's 2 peaks at 10mm and P4 peaks at 8-9mm.

DISCUSSION

The troughs visible in the balloon model profiles are suggestive of subtle hypercellularity, or "tumor cell beds", progressively invading outward from the contrast enhancing tumor boundary. Currently, radiological progression is defined as an increase in contrast enhancement, and this preliminary study for illustrates tumor invasion detectable prior to contrast enhancement. This new image processing technique presents potential as a biomarker for tumor invasion allowing predictive modeling of regions with recurrence potential. Unlike methods which measure temporal change in ADC values (2), these models find spatial change in ADC, and are able to be created using one time point's data. Further histological validation studies are needed.

ACKNOWLEDGEMENTS Funding: MCW Translational Brain Tumor Program; Advancing a Healthier Wisconsin; NIH/NCI: R21 CA109820; R01 CA082500 MCW Cancer Center.

REFERENCES

- Jenkinson MD, du Plessis DG, Smith TS, Joyce KA, Warnke PC, Walker C: Histological growth patterns and genotype in oligodendroglial tumours: correlation with MRI features. *Brain* 129:1884-1891, 2006.
- Moffat BA, Chenevert TL, Lawrence TS, Meyer CR, Johnson TD, Dong Q, Tsiens C, Mukherji S, Quint DJ, Gebarski SS, Robertson PL, Junck LR, Rehemtulla A, Ross BD: Functional diffusion map: a noninvasive MRI biomarker for early stratification of clinical brain tumor response. *Proc Natl Acad Sci U S A* 102:5524-5529, 2005.

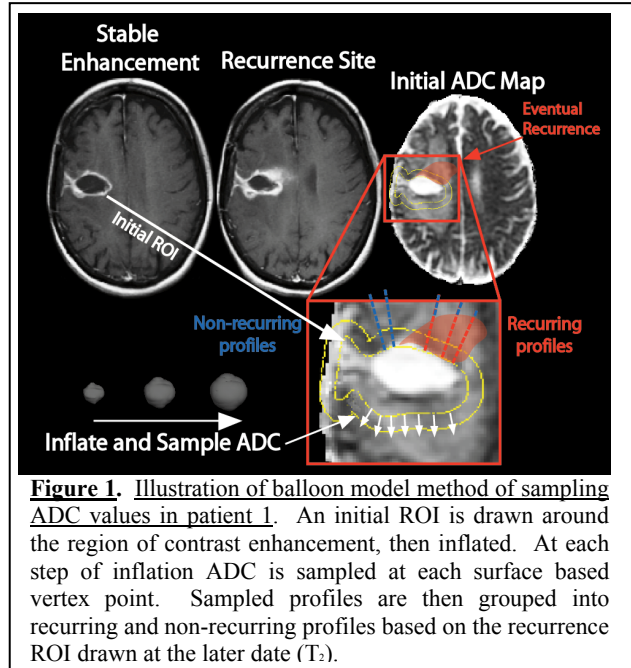


Figure 1. Illustration of balloon model method of sampling ADC values in patient 1. An initial ROI is drawn around the region of contrast enhancement, then inflated. At each step of inflation ADC is sampled at each surface based vertex point. Sampled profiles are then grouped into recurring and non-recurring profiles based on the recurrence ROI drawn at the later date (T_2).

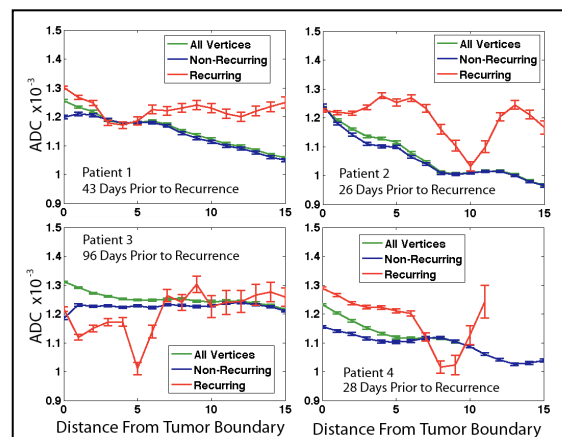


Figure 2. Results from the tumor profiles from each patient. Data are averaged at each radial distance from initial tumor ROI from 0-15mm. Each patient exhibits a zone of decreased ADC, indicative of tumor invasion and hypercellularity.