

ALTERED CORTICAL THICKNESS IN YOUNG CANNABIS ABUSERS

D. Yurgelun-Todd^{1,2}, P. Bogorodkzi³, M. Lopez-Larson^{1,2}, R. Kurjata³, J. Churchwell¹, and J. Rogowska⁴

¹Brain Institute, University of Utah, Salt Lake City, UT, United States, ²VISN 19 MIRECC, Salt Lake City, UT, United States, ³Institute of Radioelectronics, Warsaw Technical University, Warsaw, Poland, ⁴Brain Imaging Center, McLean Hospital/Harvard Medical School, Belmont, MA, United States

Purpose

Adolescence is a period of substantial cortical pruning and altered cortical thickness may be indicative of disruptions of normal cortical development. There is also evidence that early initiation of MJ use increases risk for MJ dependence in adulthood and magnetic resonance imaging (MRI) techniques have revealed that MJ users who initiate use before the age of 17 have decreased cortical grey matter in comparison with abstinent adolescent MJ abusers.^{1,2} Further, functional magnetic resonance imaging (fMRI) studies have shown altered activation in prefrontal cortical (PFC) and insula (INS) regions in abstinent adolescent MJ abusers performing tasks requiring cognitive demand such as working memory and behavioral inhibition.^{3,4} However, it is unknown whether altered cortical thickness during adolescence is associated with MJ use. This investigation used cortical-surface based techniques to compare MJ using adolescents and HC.

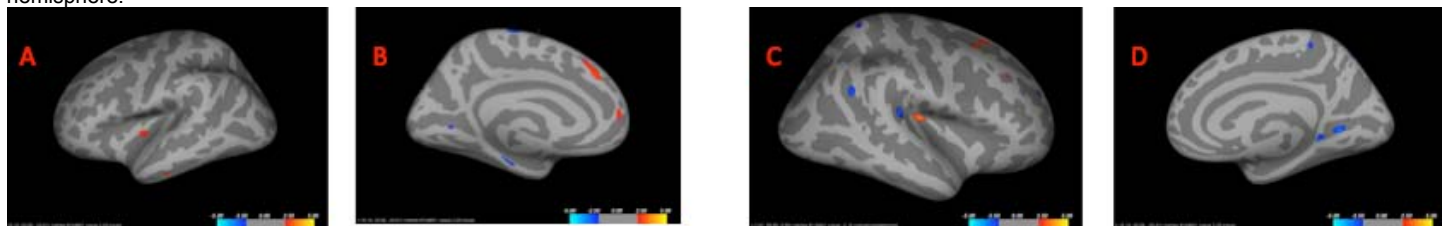
Method

Eighteen older adolescents (aged 17.8±1.0 years; females: n=2), with DSM-IV MJ Dependence and no current or prior psychiatric history or psychotropic medication use and eighteen HCs similar in age (17.3±0.8 years; females = 6) received MRI scans using a 3T Siemens Trio scanner. Structural acquisitions include a T1-weighted 3D MPRAGE grappa sequence acquired sagittally (TE/TR/TI=3.37ms/2.0s/1.1s, 8°flip, 256x256 acquisition matrix, 256mm² FOV, 160 slices, 1.0 mm slice thickness). Cortical reconstruction and volumetric segmentation was performed with the Freesurfer image analysis suite, which is documented and freely available for download online (<http://surfer.nmr.mgh.harvard.edu/>). This method uses both intensity and continuity information from the entire three dimensional MR volume in segmentation and deformation procedures to produce representations of cortical thickness, calculated as the closest distance from the gray/white boundary to the gray/CSF boundary at each vertex on the tessellated surface. Second level analysis of Group differences in cortical thickness were assessed with ANOVA with age, gender and thickness as a covariates. Statistical maps showing differences in cortical thickness between MJ and HC groups were generated. Red color was used for positive differences (HC thickness > MJ thickness) and blue for negative differences (MJ thickness > HC thickness). The most significant regions were thereafter analyzed with UNIANOVA's model with average cortical thickness of the entire parcellated region, covarying for age, and sex. Spearman's correlations were calculated for demographic data for statistically significant brain regions.

Results

Marijuana users reported their age of first MJ use was 14.9 ±1.3 and the average frequency of MJ use was 10.4±8 times/week. In addition, average MJ urine levels obtained on the day of MRI scanning were 444.2±361.5 ng/mL. Compared to HCs, MJ users had decreased cortical thickness in right (coordinate: -1,46,47; z=2.8) and left (coordinate: 29,75,30; z=2.62) superior frontal cortex and right (coordinate: 20,3,-9; z=3.7) and left (coordinate: -18,21,25; z=2.62) insula. Left and right superior frontal cortex volumes were entered in a UniANOVA, and when covaried for age and sex were not found to be significantly different. The average cortical thickness of each insular region was summed prior to UNIANOVA analysis. The right insula was found to be significantly reduced in MJ smokers compared with HC (F=4.511, p=0.01). Furthermore, the average thickness of the right insula was found to negatively correlate with age of first MJ use (r=-0.533, p=0.02).

Figure 1. The average statistical map of differences in cortical thickness in MJ users versus HC. Color scale represents thinning with red to yellow indicating areas of significant cortical thinning in MJ users compared to HC on the A) left lateral, B) left medial, C) right lateral, and D) right medial hemisphere.



Conclusions

This is one of the first studies to evaluate gray matter cortical thickness in a group of adolescents with heavy MJ use compared to HC. Our findings are consistent with prior studies that have documented abnormalities in prefrontal and insular regions.^{1,2} The insula is thought to be involved in perception, motor control, self-awareness, cognitive functioning, and interpersonal experience. The right anterior insula also aids interoceptive awareness of the body states. Moreover, greater right anterior insular gray matter volumes have been correlated with increased accuracy in the subjective sense of the inner body, and with negative emotional experience.⁶ A reduced ability to accurately perceive an inner subjective or negative emotional state may lead to potential anxiety and increased urges to use. This is supported by prior data of abnormal insula activity in abstinent adolescent MJ abusers.^{3,4} Our findings also suggest that age of first use may have an impact on cortical gray matter, particularly the insula, in the developing brain. Additional studies of cortical gray matter in MJ dependence during development are warranted.

1. Chen, O'Brien, S. M., & Anthony, J. C. (2005). Who becomes cannabis dependent soon after onset of use? Epidemiological evidence from the United States: 2000-2001. *Drug Alcohol Depend*, 79(1), 11-22.
2. Wilson, W., Mathew, R., Turkington, T., Hawk, T., Coleman, R. E., & Provenzale, J. (2000). Brain morphological changes and early marijuana use: a magnetic resonance and positron emission tomography study. *J Addict Dis*, 19(1), 1-22.
3. Padula, C. B., Schweinsburg, A. D., & Tapert, S. F. (2007). Spatial working memory performance and fMRI activation interaction in abstinent adolescent marijuana users. *Psychol Addict Behav*, 21(4), 478-487.
4. Tapert, S. F., Schweinsburg, A. D., Drummond, S. P., Paulus, M. P., Brown, S. A., Yang, T. T., et al. (2007). Functional MRI of inhibitory processing in abstinent adolescent marijuana users. *Psychopharmacology (Berl)*, 194(2), 173-183.
5. Dale, A.M., Fischl, B., Sereno, M.I., 1999. Cortical surface-based analysis. I. Segmentation and surface reconstruction. *Neuroimage* 9, 179-194.
6. Critchley HD, Wiens S, Rotshtein P, Ohman A, Dolan RJ. (2004). Neural systems supporting interoceptive awareness. *Nat Neurosci*. 7(2):189-95.

SUPPORTED by DA020269