

# Impaired Default-Mode Networks of Affective Disorders: evidences of image-guided proton MRS

T-C. Yeh<sup>1,2</sup>, C-Y. Lin<sup>2</sup>, C-W. Ko<sup>3</sup>, T-P. Su<sup>4</sup>, W-Y. Guo<sup>5</sup>, J-C. Hsieh<sup>2</sup>, and L-T. Ho<sup>1</sup>

<sup>1</sup>Department of Medical Research and Education, Taipei Veterans General Hospital, Taipei, Taiwan, <sup>2</sup>Institute of Brain Science, National Yang-Ming

University, Taipei, Taiwan, <sup>3</sup>Department of Computer Science and Engineering, National Sun Yat-sen University, Kaohsiung, Taiwan, Taiwan,

<sup>4</sup>Department of Psychiatry, Taipei Veterans General Hospital, Taipei, Taiwan, <sup>5</sup>Department of Radiology, Taipei Veterans General Hospital, Taipei, Taiwan,

Taiwan

## Introduction

Default-mode network (DMN) of resting rhythm has been detected by utilizing BOLD-based fMRI at both 1.5T and 3T field strength (Gusnard et al, 2001; Yeh et al, 2005). And DMN spatial template of human brain has been constructed for the optimal solution for the automatic detection of default networks using brain fMRI studies (Lin et al 2008). DMN spatial template showed precuneus and posterior cingulate areas (Brodmann area 31, BA31) with highest reproducibility, as indicated by previous deoxy-glucose positron emission tomography (FDG PET, Raichle et al 2001). As high resting metabolic rate of DMN was implied by these studies, localized image-guided proton magnetic resonance spectroscopy (ig-HMRS) was designed for probing the total creatine (TC) content of DMN as the phosphocreatine (PCr) for bio-energetic buffer in patients of affective disorders, including major depressive disorder (MDD) and bipolar disorder (BD). Two strategies of ig-HMRS study included (1) real-time localization MRS was guided by the Talairach space and spatial template of DMN and (2) linear correlation and correction of tissue components were applied for quantitative proton MRS.

## Subjects and Methods

### (1) Constructing spatial template of resting DMN

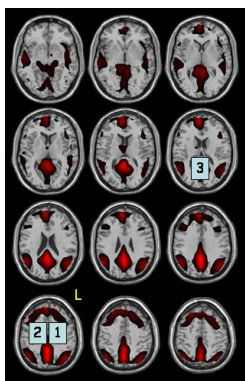
An fMRI database of sixty right-handed subjects (gender- and age-matched, age: 32 +/- 7 years old) was constructed for mapping the spatial template of DMN. Imaging studies of resting state were obtained with eye fixation. Images were acquired using a 3T Medspec S300 system (Bruker GmbH, Ettlingen, Germany) equipped with an actively shielded gradient coil and a quadrature transceiver of head. Image sequences included (1) single-shot echo planar images of fMRI (64x64 matrix, voxel size = 3.6x3.6x6 mm, 20 slices, TR/TE=2000/50 milliseconds, repetition number (NR) = 200) and structural image of MDEFT (256x256x128 matrix, voxel size = 0.98x0.98x1.5 mm). Processing of DMN spatial template included (1) preprocessing of individual data sets using SPM2 (Functional Imaging Laboratory, UCL, UK) was applied for spatial normalization; (2) Group ICA was applied to construct the spatial template of DMN using GIFT (Calhoun et al, 2001) of informax ICA (Computational Neurobiology Laboratory, The Salk Institute for Biological Studies, USA) with fixed component number of 50 by MDL (minimum description length); (3) temporal course of DMN was derived for each individual from GIFT as the regressor for GLM estimation after co-registration/normalization to MNI T1 template and smoothing of 8x8x8 mm in SPM2. Group analyses using two-level statistical evaluation of random-effect analysis was performed for DMN template of 60 subjects (DMN-60) with statistical criteria of p<0.05/voxel extension>0 for the second level with correction of false discovery rate.

### (2) ig-HMRS of affective disorders and normal subjects

Gender-balanced and age-matched normal subjects and affective disorders (N=18, 22 and 20 for normal subjects, BD and MDD, respectively; age: 34 +/- 7 years old) were recruited for ig-HMRS study using 1.5T MRI (Twin-Excite, GE, USA). All subjects were evaluated by MINI (MINI International Neuropsychiatric Interview, Taiwanese Society of Psychiatry) or conventional psychiatric interviewing for classification based on DSM-IV criteria. And all subjects of affective disorders were in euthymic state under treatments. High-resolution T1-weighted anatomical images were also acquired using the 3D spoiled gradient echo sequence (TR= 8.5ms, TE=1.8ms, voxel size = 1.0x1.0x1.5 mm). Off-line normalization was obtained immediately using 3D T1 images by AFNI (Analysis of Functional NeuroImaging, NIMH, NIH, USA). Image-guided localized H-MRS (TE/TR/NR=270ms/1500ms/128, voxel size = 2x2x2 cm) was obtained for left/right BA24 and the midline precuneus/posterior cingulate (PC) of DMN-60 template (**Figure 1**) based the transformed coordinates from AFNI. Off-line spectral quantification of H-MRS was performed using LCModel based on non-water-suppression spectra. Tissue segmentation using SPM5 (Functional Imaging Laboratory, UCL, UK) provided the factor for correcting tissue components of each MRS voxel (e.g. partitions of gray matter, white matter and cerebrospinal fluid).

## Results

Spectral quality of all localized MRS data was verified by FWHM of water peak (< 5 Hz) and water suppression (>95%). With LCModel and correction of tissue components, total creatine (TC) concentration of precuneus/posterior cingulate of DMN template [(x, y, z) = (-2, -52 32) in Talairach space] was higher in normal subjects (N=18) than those of affective disorders (N=22 and 20 for BD and MDD, respectively; **Table 1**), when TC of left BA24 in normal subjects was much higher than that of BD. N-acetylaspartate (NAA) concentration dramatically decreased in left BA24 and PC in MDD group (p=0.001~0.005).



▲ **Figure 1** : Voxel location of ig-HMRS indicated left BA24 (1), right BA24 (2) and posterior cingulate of DMN template (3). Spatial template of DMN was shown as red-color region in normalized space.

Control				BD				MDD			
	Cho	Cr	NAA		Cho	Cr	NAA		Cho	Cr	NAA
Lt BA24	1.30(0.15)	2.64(0.35)	7.74(0.94)	Lt BA24	1.18(0.21)	2.09(0.42)	6.32(0.94)	Lt BA24	1.18(0.24)	2.29(0.43)	5.86(0.88)
Rt BA24	1.09(0.19)	2.26(0.32)	6.29(0.94)	Rt BA24	1.36(1.15)	1.97(0.40)	6.16(1.29)	Rt BA24	1.13(0.23)	2.10(0.35)	5.68(0.75)
Post Cingulate	0.94(0.20)	2.88(0.43)	7.37(0.71)	Post Cingulate	0.86(1.13)	2.50(0.31)	6.62(1.10)	Post Cingulate	0.71(0.16)	2.18(0.36)	5.56(0.91)

▲ **Table 1** : Quantitative ig-HMRS indicated higher total creatine concentration (mM) in posterior cingulate region of DMN in normal as compared to affective disorders (BD or MDD). (▲: p=0.001; @: p=0.005; #:p=0.01; by two-tailed Student t-test)

## Discussion and Conclusion

Correlates of DMN spatial template mainly involved posterior medial parietal regions for interpretation of internal/external environment. With the ig-HMRS results by LCModel and correction of tissue components, higher total creatine (TC) concentration of precuneus/posterior cingulate (BA31) suggested the preserved bioenergetics or functional integrity in DMN of normal subjects as compared to affective disorders, either BD or MDD. For BD group but not MDD, attenuation of TC in left BA 24 supported the role of biomarker for left BA24. Prominent neural loss of MDD was suggested by NAA of left BA24 and PC.

## Acknowledgement

This study was supported by grants of ME-093-CP-15 and NSC-97-2752-B-010-001-001-PAE.

## References

Gusnard and Raichle 2001 Nat. Rev. Neurosci. 2: 685; Yeh T-C et al 2005, 14th Annual Meeting, Society of Magnetic Resonance, p 1523; Lin et al 2008, 14<sup>th</sup> Annual Meeting, Human Brain Map, 325 M-AM; Raichle, ME. et al 2001, Proc Natl Acad Sci USA, 98:676