

Aberrant Neurodevelopment of the Social Cognition Network during Adolescence in Autism Spectrum Disorders

C-W. Lan¹, K-H. Chou², I-Y. Chen³, Y-W. Cheng³, J. Decety⁴, Y-T. Fan³, and C-P. Lin^{1,3}

¹Institute of Biomedical Imaging and Radiological Sciences, National Yang Ming University, Taipei, Taiwan, ²Institute of Biomedical Engineering, National Yang Ming University, Taipei, Taiwan, ³Institute of Neuroscience, National Yang Ming University, Taipei, Taiwan, ⁴Departments of Psychology and Psychiatry, The University of Chicago, Chicago, United States

Introduction

Autism spectrum disorders (ASD), a pervasive neurodevelopmental disorder, is characterized by impaired social reciprocity, communication difficulties, restricted interest and stereotyped behavior [1]. Recent evidence has suggested cascade failure of brain development is likely the core deficit of ASD [2]. A number of studies has reported that the ASD brain undergoes a period of precocious growth during early postnatal life, followed by a deceleration in age-related growth [3-4]. However, that whether this abnormal brain enlargement persists into adolescence is not so clear, and the neurodevelopment is an accelerated rate of normal processes or an entirely abnormal process unique to ASD also needs to be addressed. In order to assess the convergent evidence on the developmental changes associated with neuroanatomical abnormalities in ASD, the present study used T1 Voxel Based Morphometry (T1-VBM) to clarify whether ASD might fail to fulfill neurodevelopmental maturation during adolescence as evidenced by a significant interaction with age by groups (ASD vs. control) on VBM analysis.

Materials and Methods

25 non-medicated ASD participants (mean age: 13.7±2.5 y/o) and 25 typically developing adolescents (mean age:13.5±2.1 y/o) were enrolled in the study. All participants were right-handed Chinese males with IQ > 80 as estimated by Wechsler Intelligence Scale for Children (Mean IQ for ASD group: 101.6±18.9; Mean IQ for healthy group: 109.0±9.5). These two groups were matched in age, gender, IQ and handedness. The diagnosis of ASD was confirmed using the DSM-IV diagnostic criteria as well as the Autism Diagnostic Interview-Revised (ADI-R). All MR scans were performed on a 1.5 T MR system (Excite II; GE Medical Systems, Milwaukee, USA) equipped with an 8-channel head coil. Whole brain T1-weighted images were acquired using 3D FLAIR-FSPGR with TR/TE=8.548/1.836s, TI=400ms, Flip angle =15°, voxel size=1.02*1.02*1.5 mm³. An optimized T1-VBM protocol [5] was used in this study. All image preprocessing were performed on the SPM2 (Wellcome Department of Imaging Neuroscience, London, UK). For the T1-VBM results, ANCOVA was employed with co-varying for the total gray matter (GM) volume, the participant's age, and full-scale IQ to uncover the differences between groups in gray matter volume. An uncorrected *P*-value < 0.001 as well as a cluster size of more than 10 contiguous voxels was set to putatively detect significant between-group differences. In order to overcome multiple comparison problem, all of the significant clusters were further required to pass through the following statistical criteria: small volume correction with FWE corrected *P* value < 0.05. To further elucidate different developmental pattern between the two groups, we performed a voxel-by-voxel interaction analysis to test for areas showing linear interactions between groups and age. The statistic criteria of this interaction analysis were the same as described above.

Results

Global Gray and White Matter Volume Difference Between Two Groups

Neither GM (ASD: 0.66±0.0 liters; Control 0.65±0.06 liters; *Z*=-0.18, *P*=0.78) nor WM (ASD: 0.41±0.04 liters; Control 0.43±0.04 liters; *Z*=-0.18, *P*=1.62) volume showed global differences between groups. The total intracranial volume of the ASD subjects (1.07±0.07 liters) was similar to that of the controls (1.08±0.09 liters) (*Z*=-0.67, *P*=0.65). The gray-white absolute volume ratio was 1.60 for ASD and 1.53 for controls respectively.

Regional Gray Matter Volume Difference Between Two Groups

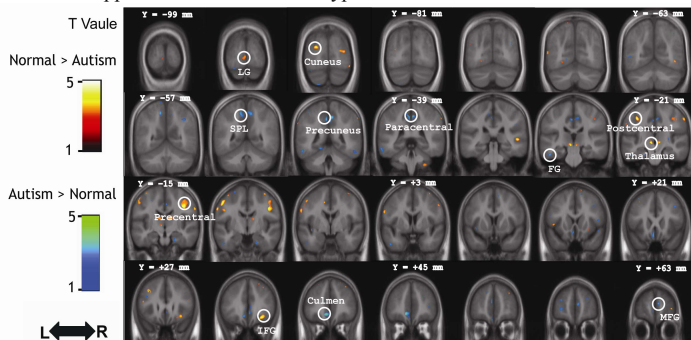
The exploratory analysis revealed individuals with ASD exhibited smaller GM volume in the right inferior frontal gyrus, precentral gyrus, postcentral gyrus, cuneus, right superior temporal gyrus and lingual gyrus. The regions that exhibited larger volumes in ASD were the cerebellum, paracentral lobule, superior parietal lobule, medial prefrontal gyrus, fusiform gyrus, middle frontal gyrus and subcallosal gyrus.

Interaction of Age by Groups

The right inferior parietal lobule and posterior cingulate of the adolescents with ASD showed a negative correlation with age whereas the controls displayed the opposite pattern. For the right inferior parietal lobule, the GM content with age had a significantly positive correlation in the control (*r* = 0.652, *P* = 0.001) but a negative correlation in the ASD (*r* = -0.434, *P* = 0.034). Additionally, the posterior cingulate had a significant interaction (controls: *r* = 0.672, *P* = 0.001; ASD: *r* = 0.021, *P* = 0.921).

Conclusions

In terms of global comparison, the present findings pointed out that the brain enlargement early in ASD childhood did not persist into adolescence. Regionally, imbalance GM volumes of participants with ASD appear in line with previous reports [6-7]. Notably, the right inferior parietal lobule and posterior cingulate showed a significant interaction of age throughout adolescence by groups as indicated by an accelerated age-related loss of GM volume in ASD whilst an age-related gain in control. We also found that the medial prefrontal cortex had a larger volume while the lingual cortex had a smaller volume, was in line with previous reports that described the frontal lobe as having the greatest enlargements and the occipital lobes having the least [8]. This may suggest that the cortical areas affected most in ASD are phylogenetically and ontogenetically late-developing regions that are essential to complex human cognitive functions such as executive function and social interaction. The current MRI study with the use of voxel-based morphometry provide evidence on the presence of aberrant development in the social cognition network, including inferior parietal lobule and posterior cingulate, during adolescence in ASD. These findings may lend indirect supports to the social brain hypothesis of autism.

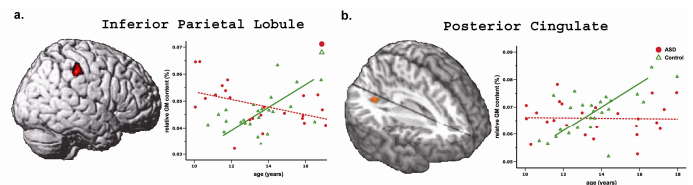


↑ Figure 1. Direct Comparison between ASD and healthy subjects;

The gray matter regions show significant group differences between individuals with ASD and controls. (Red : Normal>ASD ; Blue : ASD>Normal)

Acknowledgements

This study was supported in part by National Science Council grant NSC 98-2923-B-010-001-MY3.



↑ Figure 2. Significant Interaction of Age by Group in the Relative Gray Matter Content.

a. Inferior Parietal Lobule. An accelerated age-related loss of regional gray matter volume in the adolescents with ASD whilst an age-related gain in the healthy control.

b. Posterior Cingulate. There is no age-related change in ASD but an age-related gain in the controls.

Reference

- [1] Amaral et al., Trends Neurosci 2008.
- [2] Bailey et al., J Child Psychol Psychiatry 1996.
- [3] Courchesne et al., Ment Retard Dev Disabil Res Rev 2004.
- [4] Dementieva et al., Pediatr Neurol 2005.
- [5] Ashburner et al., Neuroimage 2000.
- [6] Hazlett et al., Biol Psychiatry 2006.
- [7] Ke et al., Neuroreport 2008.
- [8] Belmonte et al., J Neurosci 2004.