

Decreased Anterior Cingulate Cortex GABA in Depressed Adolescents Measured by Proton MRS at 3T

V. Gabbay¹, X. Mao², Y. Katz¹, A. Pazner¹, J. S. Babb¹, and D. C. Shungu²

¹NYU Child Study Center, NYU School of Medicine, New York, NY, United States, ²Radiology, Weill Cornell Medical College, New York, NY, United States

Background: Adolescent major depressive disorder (MDD) is a serious public health concern, which is associated with significant morbidity, and, most critically, with suicide. A large body of evidence has implicated the anterior cingulate cortex (ACC) (Figure 1a, b) in MDD. Evidence, including significant reductions in mean gray matter volume of the subgenual portion of the ACC, has been reported in familial MDD, and attributed to glial elements reduction in a postmortem study.¹ Metabolic dysregulation of γ -aminobutyric acid (GABA) and glutamate, which are respectively, the major inhibitory and excitatory neurotransmitters in the CNS, has been hypothesized to contribute to impaired cellular survival in MDD. Thus, there is a great of interest in measuring *in vivo* brain GABA in MDD using ¹H MRS, which is the only noninvasive neuroimaging technique that allows brain noninvasive measurements of this amino acid neurotransmitter in the living brain, by enabling its discrimination from the much stronger overlapping resonances for tCr, NAA, and glutamate+glutamine (generally referred to as "Glx"). While ¹H MRS evidence of decreased Glx in the ACC of pediatric MDD patients has been reported,² there have been no reports to date of uncontaminated GABA measurements in adolescent MDD. In this study we aimed to measure ACC GABA levels in adolescents with MDD and in healthy comparison subjects. We hypothesized that adolescents with MDD would have significantly decreased ACC GABA compared to healthy controls.

Methods: The study subjects consisted of 10 adolescents with MDD and 18 healthy controls. Adolescents and parents were interviewed by a child and adolescent psychiatrist using the Schedule for Affective Disorders and Schizophrenia-Present and Lifetime Version for Children. MDD episode duration had to be ≥ 6 weeks, and Children's Depression Rating Scale-Revised scores ≥ 36 . All subjects were psychotropic medication-free for more than 3 months and had negative day-of-scan urine toxicology, including benzodiazepines. Clean GABA signal detection was achieved by ¹H MRS on a GE 3T "EXCITE" MR system and an 8-channel phased-array head coil using the standard J-editing difference method (Figure 1c,d). GABA levels were expressed semi-quantitatively as ratios relative to the unsuppressed ACC voxel tissue water. Analysis of covariance based on ranks compared the MDD and control groups while adjusting for age, gender, and ethnicity.

Results and Discussion: As hypothesized, ACC GABA concentrations were decreased in adolescents with MDD compared to healthy controls (0.0024 ± 0.0005 versus 0.0027 ± 0.0003 , $F=5.34$, $df=21$, $p=0.031$). Our finding of a significant decrease of brain GABA in adolescent MDD is along the line of previous MRS studies in adult MDD that reported increased levels of this neurotransmitter on OCC and ACC, suggesting similar neurochemicals basis or etiology for adult and adolescent MDD. Interestingly, however, is that a number of anti-depressants that have proved effective in adults have had limited success in adolescent MDD. Examination of larger samples and rigorous comparisons are clearly necessary to establish whether there are significant differences between adolescent and adult MDD.

Conclusions: In biological research of mood disorders, it is critical to study pediatric populations to capture neurobiological processes prior to the effects of chronicity and treatment. Our finding of abnormal GABA in adolescent MDD supports the notion that GABA abnormalities seen in adult MDD play an early and potentially important role in the pathophysiology of the disorder.

1. Ongur, D., Drevets, W. C. & Price, J. L. Glial reduction in the subgenual prefrontal cortex in mood disorders. *Proc.Natl.Acad.Sci.U.S.A* 95, 13290-13295 (1998).
2. Mirza, Y. et al. Reduced anterior cingulate cortex glutamatergic concentrations in childhood major depression. *Journal of the American Academy of Child and Adolescent Psychiatry* 43, 341-348 (2004).

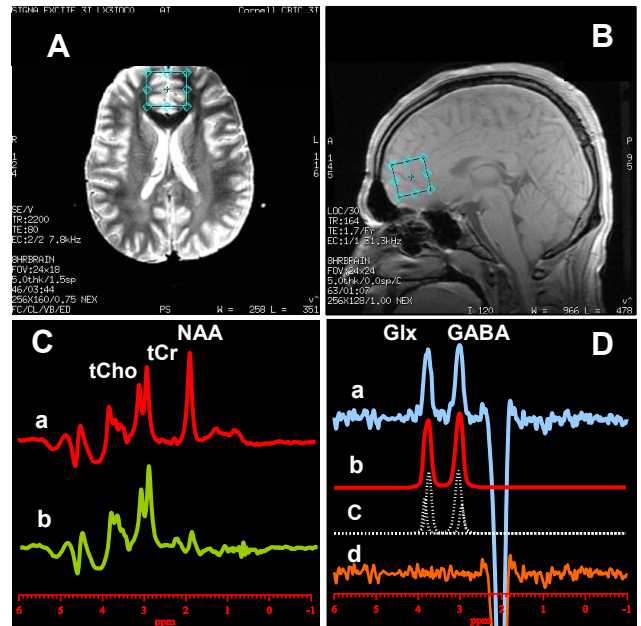


Figure 1. [A] axial and [B] sagittal images showing ACC voxel size and location; [C] PRESS ¹H MR spectra with editing rf pulse [a] off and [b] on. Note that with the editing pulse off, a standard PRESS spectrum is obtained, which will yield high quality spectra for NAA, tCr and tCho in the ACC. [D] The difference of the spectra in [C] showing (a) the detected GABA and Glx peaks, with (b-d) best-fit model curves and residuals, which will yield the areas under the peaks and concentrations. The data were acquired in 13 min from a 2.5x2.5x3.0 cm³ voxel using TE/TR 68/1500 ms, and 256 interleaved excitations (total 512) with editing pulse on or off.