

WHITE MATTER ABNORMALITIES ASSOCIATED WITH NEUROLOGICAL SOFT SIGNS IN FIRST-EPISEDE SCHIZOPHRENIA: A DIFFUSION TENSOR IMAGING STUDY.

C. Rodriguez-Régent¹, S. Mouchet-Mages², S. Rodrigo³, M-O. Krebs², C. Oppenheim³, and J-F. Meder³

¹Department of Morphologic and Functional Imaging, University Paris Descartes, Sainte Anne Hospital, PARIS, France, ²Pathophysiology of Psychiatric Diseases, University Paris Descartes, Sainte Anne Hospital, PARIS, France, ³Department of Morphologic and Functional Imaging, University Paris Descartes, Sainte Anne Hospital

Background:

Schizophrenic patients often present with minor motor and sensory deficits, or neurological soft signs (NSS), which are generally viewed as “non localizing” signs. This is a well-established finding in schizophrenia but the cerebral changes underlying these signs are poorly understood. Previous Magnetic Resonance Imaging (MRI) studies have reported diffuse brain structural abnormalities associated with NSS. Diffusion tensor imaging (DTI) allows the detection of changes in the anisotropic diffusion and can measure white matter microstructural changes. This study is the first to examine the structural correlates of NSS using DTI in first-episode schizophrenia.

Methods:

Forty-five patients with first-episode schizophrenia or schizophreniform disorder were recruited and underwent DTI. **Image acquisition:** images were obtained on a 1.5 T GE healthcare magnetic resonance scanner (General Electric Medical Systems, Milwaukee, Wisconsin), with an 8-channel head coil. Axial Diffusion-weighted images were acquired using a SE-EPI sequence (TE/TR = 80/6575, Acquisition matrix = 128 × 128, FOV = 240 × 240 mm², slice thickness of 4 mm, b = 0 s/mm² and 700 s/mm², diffusion encoding along 35 directions). **Neurological examination:** NSS were assessed using a standardized neurological examination (1) and patients were split in two groups according to their NSS score (NSS- or NSS+). **Statistical analysis:** fractional anisotropy (FA), calculated using a voxel based analysis was compared between the two groups, by means of FSL software (2) and SPM (ANCOVA test). The values of FA were also correlated with the scores of NSS considered as continuous variables (linear regression test). The analyses were carried out by taking into account the psychotic status (PANSS score) as a confounding factor. The statistical threshold was $p < 0.05$ on a cluster level.

Results:

Comparison between the NSS+ and NSS- groups showed a significant decrease of FA ($p = 0.001$) in the white matter of the right prefrontal area in NSS+ group. FA was negatively correlated with the total NSS score in the left occipital area ($p = 0.049$) and with the motor coordination score in the left occipital ($p = 0.014$) and right parietal areas ($p = 0.017$).

Discussion:

Several white matter areas showed a significant decrease of FA associated with NSS. It is consistent with the clinical diversity of NSS which include motor and sensory signs and their “non localizing” value. The right prefrontal area that showed decreased FA negatively associated with the NSS score is part of the cortical-thalamic-cerebellar-cortical circuit (CCTCC). It supports Andreasen's hypothesis that schizophrenia may be a single disorder linked by a common pathophysiology which leads to a misconnection syndrome of this neural circuitry (3). By selecting patients who received little or no treatment, there is no confounding factor, both on the analysis of the cerebral white matter and on the neurological examination. The main limitation of the present study is the lack of healthy controls. However, a previous study showed that increased NSS scores were associated with brain structural changes but this pattern only applied to patients with schizophrenia but not to healthy controls (4).

Conclusion:

This first study confirms that microstructural changes of white matter are associated with NSS in schizophrenia. It suggests a disorganization of neural networks associated with NSS.

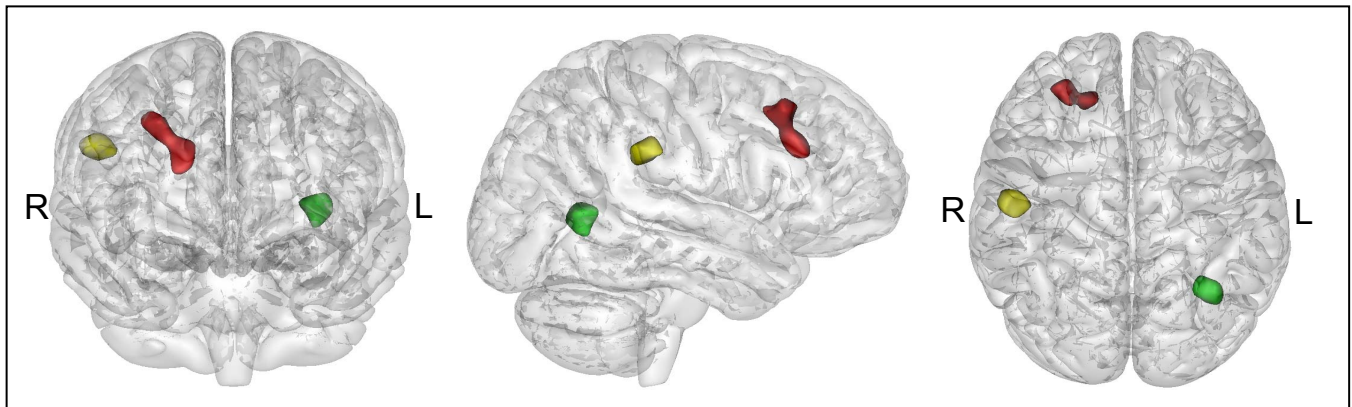


Fig1: Areas of reduced fractional anisotropy (FA) in right prefrontal (red), parietal (yellow) and left occipital (green) white matter correlated with neurological soft signs (NSS) projected on a glass brain.

1. Krebs MO, Gut-Fayard A, Bourdel M, Dischamp J, Olie J. Validation and factorial structure of a standardized neurological examination assessing neurological soft signs in schizophrenia. *Schizophr Res* 2000; 45:245-260.
2. Smith SM, Jenkinson M, Johansen-Berg H, et al. Tract-based spatial statistics: voxelwise analysis of multi-subject diffusion data. *Neuroimage* 2006; 31:1487-1505.
3. Andreasen NC, Nopoulos P, O'Leary DS, Miller DD, Wassink T, Flaum M. Defining the phenotype of schizophrenia: cognitive dysmetria and its neural mechanisms. *Biol Psychiatry* 1999; 46:908-920.
4. Thomann PA, Wustenberg T, Santos VD, Bachmann S, Essig M, Schroder J. Neurological soft signs and brain morphology in first-episode schizophrenia. *Psychol Med* 2009; 39:371-379.