

White matter lesion load in type 2 diabetes - a VBM study

L. E. Forsberg^{1,2}, S. Sigurdsson³, T. Aspelund^{3,4}, J. Fredriksson², S. Kristinsson², Ó. Kjartansson³, B. Óskarsdóttir³, P. V. Jónsson^{3,4}, G. Eiríksdóttir³, T. B. Harris⁵, M. A. van Buchem⁶, A. Zijdenbos⁷, L. J. Launer⁵, and V. Gudnason^{3,4}

¹Department of Neuroscience, Karolinska Institutet, Stockholm, Sweden, ²Raförminn ehf, Reykjavik, Iceland, ³Icelandic Heart Association, Kopavogur, Iceland, ⁴The University of Iceland, Reykjavik, Iceland, ⁵Laboratory of Epidemiology, Demography, and Biometry, National Institute of Aging, Bethesda, MD, United States, ⁶Department of Radiology, Leiden University Medical Center, Leiden, Netherlands, ⁷Biospective Inc., Montreal, Canada

Introduction

It is known that type 2 diabetes (DM2) is a risk factor for white matter lesions (WML) in the brain. The common distribution of these lesions is however less known. In this study, we examined the common distribution of WML in DM2 compared to non-diabetic controls using voxel-based morphometry (VBM).

Materials and method

Magnetic resonance images (T1, T2, PD, and Flair) of 4614 subjects (1934 men and 2680 women, mean age 76±6 years) from the Age, Gene/Environment Susceptibility (AGES)-Reykjavik Study were registered to the ICBM152 template and segmented into grey matter (GM), white matter (WM), white matter lesions (WML), and cerebrospinal fluid (CSF) using an automatic multi-spectral imaging pipeline. A subset of 1890 subjects, 215 subjects with DM2 (113 men and 102 women) and 1675 non-diabetic control subjects (665 men and 1010 women), was used for the VBM analysis. Mean±SD age of the DM2 group and the control group were 76.1±5.4 years and 75.8±5.6 years respectively. Tissue masks for WML in MNI space were filtered with a FWHM Gaussian filter of 10 mm prior to the statistical analysis. The filtered WML masks were used in the VBM analysis as a dependent variable. Age, sex and DM2 were used as independent variables. A student-t image was obtained from the analysis where differences in WML were observed. False discovery rate (FDR) was used to adjust for family-wise error, with $p < 0.01$.

Result

The VBM result shows a significant difference in WML load between DM2 and controls. A threshold value of 3.58 was obtained for the student-t image when adjusting for family-wise error using FDR ($p < 0.01$). This results in two lateral areas, which together have a total size of 348 cm³. Both areas extend from the frontal lobe to the parietal lobe, and with most of the WML in the frontal lobe.

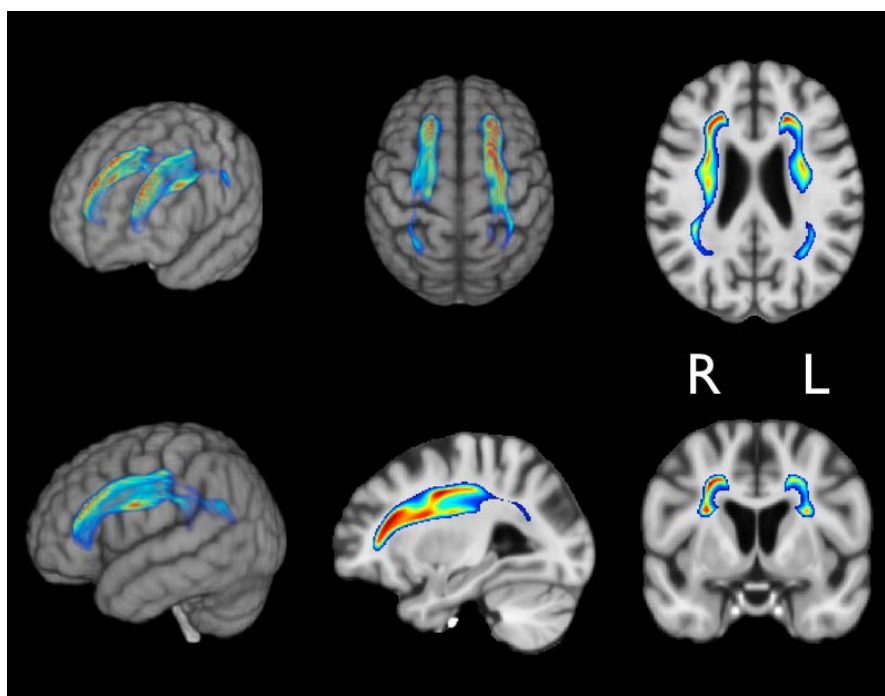


Figure 1: VBM result visualised on a symmetric standard brain. The sagittal slice represents the right hemisphere. The colour map for the WML shows more significant voxels in red and less significant voxels in blue.

Conclusion

This study shows where in the brain DM2 subjects have common areas of WML in the brain when compared to controls. Our finding is that these areas are large and extend from the frontal lobe to the parietal lobe.