

# Cerebral accumulation of 3-hydroxyisovaleric acid in adults until recently unaware of having 3-Methylcrotonyl-CoA Carboxylase (MCC) deficiency

M. van der Graaf<sup>1,2</sup>, U. F. Engelke<sup>3</sup>, E. Morava<sup>4</sup>, M. C. Janssen<sup>5</sup>, M. C. de Vries<sup>4</sup>, L. A. Kluijtmans<sup>3</sup>, B. Goraj<sup>1</sup>, A. Heerschap<sup>1</sup>, and R. A. Wevers<sup>3</sup>

<sup>1</sup>Radiology, Radboud University Nijmegen Medical Centre, Nijmegen, Netherlands, <sup>2</sup>Clinical Physics Laboratory, Radboud University Nijmegen Medical Centre, Nijmegen, Netherlands, <sup>3</sup>Laboratory of Genetic, Endocrine and Metabolic Diseases, Radboud University Nijmegen Medical Centre, Nijmegen, Netherlands, <sup>4</sup>Pediatrics, Radboud University Nijmegen Medical Centre, Nijmegen, Netherlands, <sup>5</sup>General Internal Medicine, Radboud University Nijmegen Medical Centre, Nijmegen, Netherlands

## Introduction

3-Methylcrotonyl-CoA Carboxylase (MCC; EC 6.4.1.4) is a biotin-dependent enzyme in the L-leucine degradation pathway. MCC deficiency (MCCD) results in accumulation of 3-methylcrotonyl-CoA with subsequent conversion to 3-hydroxyisovaleric acid (3HIVA), 3-hydroxyisovalerylcarnitine, and 3-methylcrotonylglycine (Fig. 1). Reported outcomes of MCCD range from asymptomatic to death in infancy. However, the majority of identified MCCD patients (>90%) develop no symptoms and it largely presents as a nondisease [1].

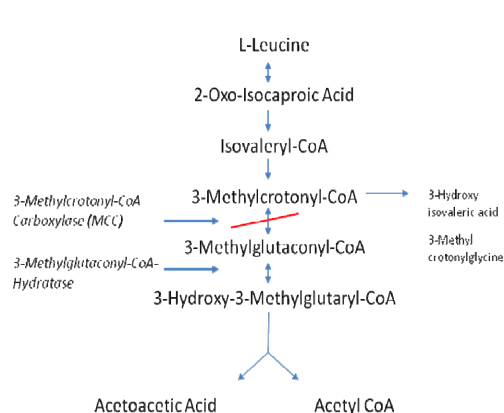
Recently, it was shown by 3T proton MRS that 3HIVA accumulated in the brain of a pediatric patient with MCCD [2]. After this finding, the patient received a low-protein diet to minimize 3HIVA accumulation. Another *in vivo* MRS and *in vitro* NMR study showed an MRS-detectable resonance of 3HIVA in cerebral white matter of an adult patient presenting with a slowly progressing leukoencephalopathy [3]. This 3HIVA accumulation originated from a defect in the enzyme 3-Methylglutaconyl-CoA Hydratase (EC 4.2.1.18), which is also involved in the L-leucine catabolic pathway (Fig. 1). It may be concluded from the latter study, that 3HIVA plays a role in the development of the leukoencephalopathy. In fact, 3HIVA has been suggested to be neurotoxic [4], but this is under debate [5].

The **aim of the present study** was to investigate whether proton MRS could detect elevated 3HIVA in adult patients with MCCD without symptoms to gain information about its neurotoxicity. It was hypothesized that the level of cerebral 3HIVA may be low in asymptomatic MCCD patients.

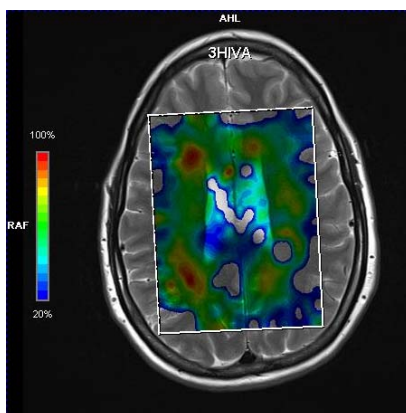
## Methods

**Subjects:** Two female patients (30 and 31 yrs old) were diagnosed with MCCD after a positive neonatal screening for MCCD in their newborn babies. The diagnosis could not be confirmed in the babies by regular metabolite screening and/or enzyme diagnostics. The diagnoses in both women were established by demonstration of high 3-methylcrotonylglycine and C5-OH-carnitine. In one woman, the enzyme deficiency was confirmed by enzyme measurement (no residual activity). Both women were unaware of having an enzyme deficiency. The 31-yr old woman had no health complaints at all and the other suffered from a depression.

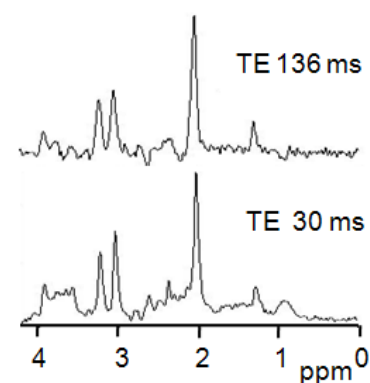
**MR measurements:** High resolution *in vitro* 1H-NMR spectra of urine samples of the patients (pH adjusted to 2.5) were acquired at 500 MHz on a Bruker DRX spectrometer, for experimental details see [3]. MRI and *in vivo* MRS measurements were performed on a Siemens Magnetom Tim-Trio System (Siemens, Erlangen, Germany) operating at 3T. The patients underwent a standard MRI protocol including T1w, T2w, FLAIR and diffusion-weighted imaging. MRS was performed using a 2D multivoxel semi-LASER sequence [6] (TEs 30 and 136 ms, TR 2000 ms) with and without water suppression to obtain multiple spectra in gray and white matter in a slab through the ventricles. In addition, single voxel MRS measurements were performed in a voxel positioned in periventricular occipital white matter using a PRESS sequence with short and long echo times (TE 30 ms, TR 5000 ms and TR 136 ms, TR 2000 ms). The data were analyzed using a combination of LCModel and jMRUI.



**Figure 1.**  
Degradation pathway of L-leucine



**Figure 2.**  
Metabolic map of 3HIVA derived from an MRSI measurement with TE 136 ms



**Figure 3.**  
White matter proton spectra acquired with short (30 ms) and long (136 ms) TE, showing the 3HIVA singlet at 1.28 ppm

## Results and Discussion

3HIVA concentrations found in urine were 1400  $\mu\text{mol}/\text{mmol}$  creatinine for the 31-yr old patient without complaints and 1990  $\mu\text{mol}/\text{mmol}$  creatinine for the other. For both patients, MRI and MRS findings were similar. MRI showed no abnormalities. MRS showed predominantly in white matter (Fig. 2) a clear single resonance of 3HIVA at 1.28 ppm (Fig. 3). Based upon the relative intensity of the 3HIVA signal originating from two methyl groups and the methyl proton signal of creatine, the brain 3HIVA concentration was roughly estimated to be in the order of magnitude of 1.1 – 1.4 mmol/L in the 31-yr old woman without complaints and 0.7 – 1.0 mmol/L in the other woman. Other brain metabolite concentrations were in the normal range.

The concentrations of cerebral 3HIVA were similar or higher than the cerebral 3HIVA concentrations published so far for MCCD [2] and 3-Methylglutaconyl-CoA Hydratase deficiency [3]. The 3HIVA levels in urine and brain seemed not to correlate. As the patient with the highest cerebral 3HIVA concentration has no complaints at all, and also the other had no clear MCCD-related symptoms, our hypothesis turned out to be false. Our results corroborate the disbelief about the neurotoxicity of 3HIVA, although no direct evidence is given.

## Conclusion

We have shown relatively high levels of cerebral 3HIVA in adult patients with MCCD, who became only recently aware of having this deficiency. As the patients had no to minor complaints, the suggested neurotoxic effect of 3-HIVA seems to be absent to low.

**References:** [1] Stadler SC et al., *Hum Mutat*, 2006;27:748-759. [2] Van der Graaf M et al., *Proc. 17th ISMRM meeting*, 2009;3476. [3] Engelke UFH et al., *NMR Biomed*, 2006;19:271-278. [4] Duran M et al., *J Inher Metab Dis* 1993;16:513-6. [5] Ribeiro CA et al., *Cell Mol Neurobiol*, 2007;27:529-540. [6] Scheenen TW et al. *Magn Reson Med*, 2008;59:1-6.