

Corpus Callosum Atrophy and Diffusion Abnormalities in Clinically Isolated Syndrome Revealed by Diffusion Tensor Tractography

F. Lin¹, C. Yu², Y. Liu², and H. Lei¹

¹Wuhan Institute of Physics & Mathematics, The Chinese Academy of Sciences, Wuhan, Hubei, China, People's Republic of, ²Department of Radiology, Xuanwu Hospital of Capital Medical University, Beijing, China, People's Republic of

Introduction Many previous studies have observed atrophy and abnormal water diffusivity within the corpus callosum (CC) of multiple sclerosis (MS) patients [1, 2]. However, few studies have addressed the question whether such abnormalities exist in the earlier stages of MS, especially in clinically isolated syndrome (CIS). In this study, we aimed to investigate CC abnormalities in CIS patients with diffusion tensor group tractography [3].

Materials and Methods Nineteen CIS patients (10F/9M; mean age: 39.5±11.6 years) and 19 age- and sex-matched healthy subjects (Con) were scanned with a T₂-weighted anatomical imaging protocol (TR/TE: 500/94 ms) and a single-shot, spin-echo EPI diffusion tensor imaging protocol (6 non-collinear diffusion-sensitizing gradient directions; in-plane resolution: 0.94×0.94 mm, 4 mm slice thickness with 0.4 mm inter-slice gap, b=0 and 1000 s/mm²) on a 1.5 T Siemens scanner. For each subject, the maps of four diffusion indices, namely fractional anisotropy (FA), mean diffusivity (MD), axial diffusivity (λ_1) and radial diffusivity (λ_{23}), were first calculated, and the midsagittal CC area was measured from the FA-weighted color-coded map. The entire CC of each healthy subject was reconstructed with DTIstudio [4], and normalized to the MNI space. A CC probability map was then generated by averaging the CC masks from all healthy subjects, which was used as a weighted template to evaluate the average diffusion indices within the CC of normal subjects and CIS patients [3]. For each CIS patients, the lesion load in the whole brain was derived manually from the T₂-weighted anatomical images. The correlations between the diffusion indices in the normal-appearing (NA) CC and the whole-brain lesion load were assessed in the CIS patients.

Results Figure 1 shows the CC probability map derived from the healthy subjects. There existed a significant inter-group difference in the midsagittal CC area (Con: 6.27±0.60 cm²; CIS: 5.50±0.64 cm²; P=0.001). Compared to the healthy subjects, the CIS patients had significantly higher MD, λ_1 , λ_{23} and significantly lower FA in the entire CC. In the CIS patients, the average FA of the NA CC correlated negatively with the whole-brain lesion load (Fig. 2), while the other three diffusion indices correlated positively with the whole-brain lesion load (Fig. 2).

Discussion In this study, we found that both the morphology and microstructure of the CC appear to be damaged at the stage of CIS. The CIS patients showed reduced midsagittal CC area relative to the healthy subjects, suggesting that the onset of CC atrophy may appear at the stage of CIS, the earliest clinical expression of MS. Abnormal diffusion within the CC was also found in the CIS patients, indicative of damaged CC integrity. In our study, the diffusion indices derived from the NA CC were found to correlate significantly with the whole-brain lesion load, reflecting the presence of Wallerian degeneration in the brain of the CIS patients.

Acknowledgements Supported by grants 30800252, 30670601 and 30470519 from Natural Science Foundation of China.

References [1] Simon JH, et al., AJNR Am J Neuroradiol, 1987 8(4):599-604. [2] Rovaris M, et al., Neurology, 2006 65(10):1526-32. [3] Lin F, et al., AJNR Am J Neuroradiol, 2007 28(2):278-82. [4] Jiang H, et al., Comput Methods Programs Biomed, 2006 81(2):106-16.

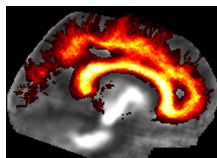


Figure 1. The probability map of the corpus callosum (CC) constructed from 19 healthy subjects. The value of each voxel in this map could be considered as the probability of that voxel being part of the CC.

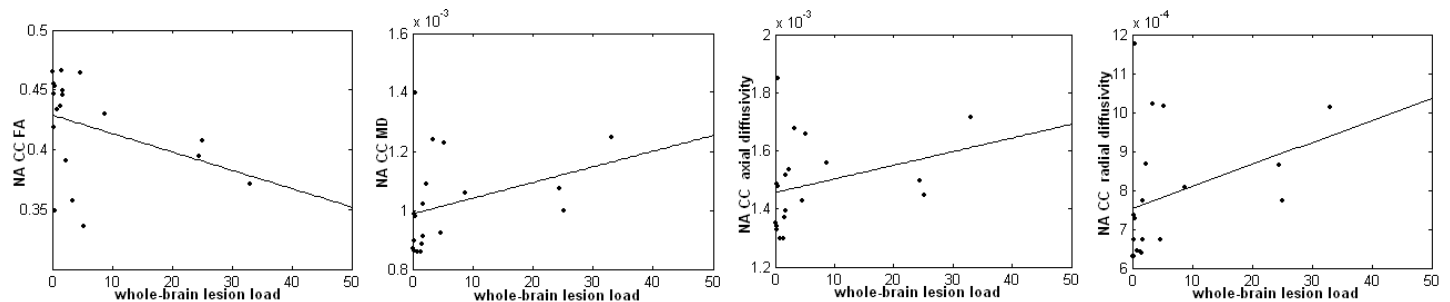


Figure 2. The fractional anisotropy (FA), mean diffusivity (MD, mm²/s), axial diffusivity (mm²/s) and radial diffusivity (mm²/s) in the normal-appearing (NA) CC of the CIS patients correlated significantly with the whole-brain lesion load (ml). FA; r = -0.502, P = 0.029; MD: r=0.554, P = 0.014; axial diffusivity: r=0.504, P = 0.028; and radial diffusivity: r=0.542, P = 0.016.