

Regional Grey-White Matter Volume Abnormalities in Children with Histories of Early Deprivation

J.-W. Jeong^{1,2}, M. Behen^{1,2}, P. Sinsoongsud^{1,2}, O. Muzik^{2,3}, B. Wilson^{1,2}, and H. T. Chugani^{2,3}

¹Pediatrics and Neurology, Wayne State University, Detroit, MI, United States, ²PET center, Children's Hospital of Michigan, Detroit, MI, United States, ³Pediatrics, Neurology, and Radiology, Wayne State University, Detroit, MI, United States

Introduction: A previous ¹⁸FDG-PET study [1] revealed that children with histories of institutional rearing show significantly decreased glucose metabolism in numerous brain regions including the orbito frontal gyrus, infralimbic prefrontal cortex, hippocampus/amygdala, lateral temporal cortex, and the brain stem. Dysfunction in these regions may result from severe stress of early deprivation and probably are associated with the cognitive and behavioral deficits commonly observed in these children. However it is not known whether abnormalities in glucose metabolism are directly related to volumetric changes of grey-white matter. This study presents an atlas-based group analysis to assess specific volumetric changes in predefined brain regions in children with histories of early deprivation and examines associations between regional volumetric findings and cognitive, socioemotional, and behavioral difficulties that commonly are observed in the orphans.

Materials and Methods: 32 children with histories of early deprivation (ED, Age: 109.44 ± 28.65 months, 6 males) and 16 normal controls (NC, Age: 144.88±27.23 months, 9 males) were recruited for this study. The ED participants had been institutionalized from birth in orphanages in Eastern Europe (n=7), Russia (n=10), or China (n=15) for 25.8±19.6 months before being adopted to U.S. families. Exclusionary criteria included FSIQ<78, pre- and/or peri-natal difficulties, and current/historical medical problems. 3-D FLASH data were acquired from all subjects on a 1.5 T SIEMENS Sonata scanner at TR = 21 ms, TE = 7 ms, field of view = 240 cm, 256x256 matrix, planar resolution of 0.94x0.94 mm² and contiguous 2 mm thickness slices to cover entire brain. Neuropsychological assessment consisted of evaluation of the following domains: global, verbal comprehension, perceptual-organizational, freedom from distractibility, and processing speed indices of intellectual functioning, expressive and receptive language processing, verbal and visual memory, executive functioning (attention, impulsivity), manual dexterity, and behavioral functioning. SPM 8 DARTEL toolbox (www.fil.ucl.ac.uk/spm) was utilized to achieve inter-subject normalization of three different tissue classes in population average space, Grey Matter (GM), White Matter (WM), and CSF. Probabilistic tissue templates were generated from 16 NC data in order to minimize normalization errors caused by subject variation on size, shape, and distribution of brain tissue. Based on these group average templates the image volumes of individual subjects were segmented into three classes. The linear/nonlinear deformations to warp all of the GM and WM images from native space to population space were estimated using the DARTEL algorithm [2]. Warped and modulated GM and WM images were then transformed to MNI space by applying an affine transformation obtained from the GM images of population average space to those of SPM MNI space. As in the standard VBM analysis, each optimally segmented/deformed/modulated GM and WM image was smoothed with an 8-mm FWHM Gaussian kernel in MNI space and used as final tissue data for statistical analysis. A total of 56 ROIs over the whole brain were defined from WFU PickAtlas in MNI space (www.wfubmc.edu/cms). These ROIs were used as binary masks to measure the total volume of GM and WM in each subject. For each ROI, the smoothed GM and WM volumes of both groups were analyzed by ANCOVA in order to assess volumetric changes between groups. Age, gender, and total intracranial volume (TIV) were included as covariates.

Results and Discussion: Fig. 1 shows multiple regions of significant volume reduction in GM (top) and WM (bottom) in the ED group compared to controls. Regional volume reduction of the GM was observed bilaterally in the frontal-inferior/middle/superior/medial-orbital gyrus (p = 0.035), temporal-inferior/middle/superior gyurs (p=0.047), temporal-pole-middle/superior gyrus (p= 0.004) and cerebellum (p=0.027). In addition, we observed a significant reductoin in WM volume bilaterally in the anterior/posterior cingulum (p=0.014) frontal-inferior/middle/suprior/medial-orbital gyrus (p = 0.030), temporal-inferior/middle/superior gyrus (p=0.022), hippocampus (p=0.038), thalamus (p=0.004), and cerebellum (p=0.041). There was no significant reduction in GM and WM in the pre-/post-central and supplementary motor cortex. Finally, in the ED group we observed significant correlations between both GM volumes and neurocognitive and behavioral domains. Specifically, significant correlations were determined between externalizing behavior problems and left temporal pole GM volumes (Figure 2) as well as between perceptual organizational intellectual

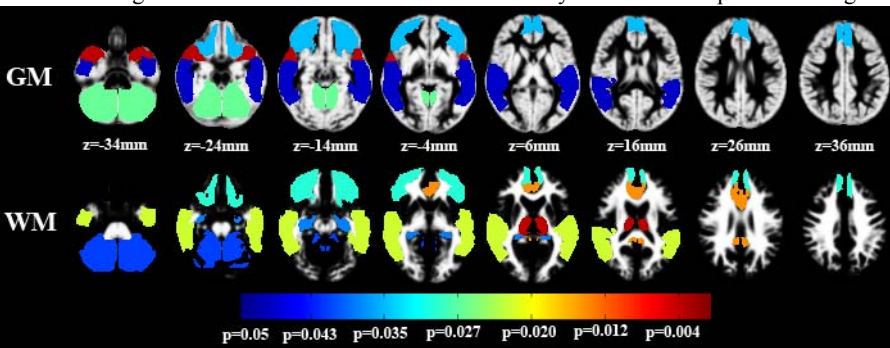
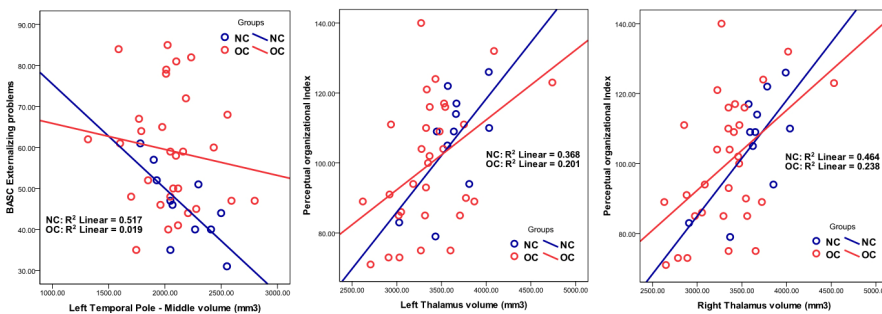


Fig.1 Atlas of significant reduction in the volume of GM (top) and WM (bottom) at significant level of p < 0.05. Colors bar represents p-value of each atlas. Gray background shows the tissue template in MNI space constructed from the SPGR data of all 16 NCs.



functioning and bilateral thalamic WM volumes. Such findings suggest that functional impairment often observed in children with histories of early deprivation are associated with regional volumetric structural changes. Further studies with larger samples are underway to validate these preliminary observations.

Reference: [1] Harry Chugani et al., Neuroimage 2001, 14:1290-1301. [2] Arno Kelin et al., Neuroimage 2009, 46:786-802.

Reference: [1] Harry Chugani et al., Neuroimage 2001, 14:1290-1301. [2] Arno Kelin et al., Neuroimage 2009, 46:786-802.

Fig.2 Correlation of externalizing behavioral problems, and perceptual-organizational intellectual functioning to regional volumes; GM of left temporal pole (left), the WM of left thalamus (middle), and the WM of right thalamus (right).