

Susceptibility-weighted imaging in pediatric epilepsy

M. Ida¹, H. Yoshizawa¹, S. Sugawara¹, Y. Kubo¹, K. Hino¹, and N. Yorozu¹

¹Department of Radiology, Tokyo Metropolitan Ebara Hospital, Tokyo, Japan

INTRODUCTION: Susceptibility-weighted imaging (SWI) exploits phase shift itself to enhance contrast caused by the susceptibility differences between tissues, and creates contrast between deoxygenated veins and the neighboring tissue in the brain [1]. SWI provides high-spatial resolution, blood-oxygen-dependent, venography without requiring contrast media. Clinically, SWI has been applied to the visualization of small developmental venous anomaly (venous malformation) and to the detection of venous congestion caused by acute venous thrombosis. We present two pediatric patients who showed prominent cortical veins with marked hypointensity on SWI in the acute stage after onset of generalized seizure, and investigate the clinical role of SWI in pediatric epilepsy.

MATERIALS and METHODS: MR examinations were performed with a clinical imager operating at 1.5-T (MAGNETOM Avanto, A Tim system, Siemens). SWI were acquired with a three-dimensional fast low-angle shot (FLASH) sequence with a TE of 40 ms, a low bandwidth (80Hz/pixel), a fully, first-order, velocity-compensated gradient moment nulling in all three orthogonal directions and 72 partitions, a voxel volume of 0.8 x 0.7 x 1.6 mm³. The coverage volume was 115 mm thick, and the total acquisition time was 6 min and 19 sec using parallel imaging.

RESULTS: Case 1; A 6-year-old male presented with a sudden-onset, generalized tonic-clonic seizure. The patient was afebrile but still in a drowsy state on admission. Emergency MR was performed 90 minutes after the onset, before starting intravenous administration of diazepam. Diffusion-weighted images (DWI) and T2-weighted images (T2WI) showed neither abnormal signal nor decrease in ADC. MRA represented normal appearance without spasm or hyperperfusion. SWI demonstrated tortuous draining veins with marked hypointensity in the left cerebral hemisphere, particularly in the left parietal lobe compared to the contralateral hemisphere (fig.1). Those SWI findings suggested increased deoxy-Hb in the draining vein and decreased oxy-Hb in the surrounding brain tissue. Electroencephalogram demonstrated slow waves with sporadic spikes in the left frontal region. Case 2; A 6-year-old female admitted with a sudden-onset, generalized tonic-clonic convulsion. Mild consciousness disturbance persisted after his arrival at the hospital. Emergency MR was carried out 2 hours after onset, before starting drug administration. DWI and T2WI showed no definite abnormality, either in the gray matter or white matter. There was no developmental anomaly or neuroepithelial neoplasm. SWI demonstrated markedly tortuous cortical veins with significant hypointensity in the right cerebral hemisphere, particularly in the parieto-occipital lobes (fig.2). The patient was improved completely without hemorrhage or infarct.

CONCLUSIONS: These two patients were diagnosed as having generalized tonic clonic seizure and postictal encephalopathy of unknown origin. Global decrease of cerebral cortical blood flow oxygen metabolism has been reported in patients with cryptogenic symptomatic epilepsy. Global decrease of rCBF and rCMRO₂ and a slightly increase in OEF were proven by positron-emission tomography [2]. It is probable that the SWI findings reflect transient misery perfusion state secondary to hyperexcitation or vasospasm in status epilepticus. Uncoupling between oxygen supply and demand in the epileptogenic excited tissue is considered to cause a relative increase of deoxy-Hb level and a decrease of oxy-Hb in the tissue capillaries and the draining veins. SWI directly detect impaired oxygen metabolism caused by increased oxygen demand of the cerebral tissue in pediatric patients with epileptic seizures. SWI has the possibility to diagnose acute postictal encephalopathy, before cytotoxic edema occurs on DWI.

REFERENCES:

[1] Haacke EM. Magn Reson Med.52 (3): 612-8, 2004

[2] Reuck JD. Clinical neurology.97: 208-212 1995

Fig.1 SWI of case 1

Prominent cortical veins in the left hemisphere

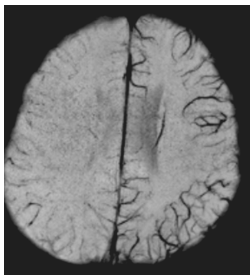


Fig.2 SWI of case 2

Increased deoxyhemoglobin in the right occipital lobe.

