

High Angular Resolution Diffusion Imaging (HARDI) Analysis of the Motor Pathway in Infants

J. I. Berman¹, S. L. Bonifacio², R. G. Henry¹, D. M. Ferriero^{2,3}, H. C. Glass², A. J. Barkovich¹, and D. Xu¹

¹Radiology and Biomedical Imaging, University of California San Francisco, San Francisco, California, United States, ²Pediatrics, University of California San Francisco, San Francisco, California, United States, ³Neurology, University of California San Francisco, San Francisco, California, United States

Introduction: During the first months of life, infants undergo rapid brain development and white matter architecture becomes highly complex. Diffusion tensor imaging (DTI) has been extensively used in pediatric populations to quantitatively assess normal and abnormal patterns of white matter development. However, the diffusion tensor model is limited to single fiber populations and fails to accurately describe complex crossing white matter pathways. The q-ball reconstruction of high angular resolution diffusion imaging (HARDI) can detect crossing fiber populations and provide more microstructural detail. Q-ball tractography has previously been shown in adults to be capable of following white matter tracts through complex white matter and more extensively delineating tracts. In this study, q-ball imaging was performed in 3 and 6 month old infants with a history of birth asphyxia. Probabilistic q-ball tractography was used to delineate the motor pathway and quantitatively assess white matter microstructure.

Methods: Three infants aged 3 months and 5 infants aged 6 months with a history of birth asphyxia were enrolled in this study and MR was performed under sedation on a GE 3T scanner. The 11.2-minute whole brain HARDI acquisition was acquired with $b=3000 \text{ s/mm}^2$, 55 diffusion gradient directions, TR/TE= 12s/96ms, voxel size=0.94x0.94x2mm, and parallel acceleration factor of 2. The q-ball reconstruction was performed to detect multiple crossing fiber populations [1,2]. Residual-bootstrap probabilistic q-ball tractography was used with multiple regions of interest to delineate the motor pathway [3]. Diffusion parameters (FA, D_{av} , and eigenvalues) calculated from the HARDI data set were measured in the 3D region defined by the fiber tractography. Left and right side measurements of each infant were averaged.

Results: Complex white matter architecture in the centrum semiovale was detected at both ages. Figure 1 shows the DTI color overlay of a 6 month old infant on the left and the q-ball orientation distribution function (ODF) on the right. The motor pathway is observed to cross the superior longitudinal fasciculus (SLF).

Tractography of the motor pathway revealed connectivity from the superior-medial and inferior-lateral portions of the motor cortex, through the centrum semiovale, to the midbrain (figure 2). Tract-specific FA was observed to increase significantly with age ($p<0.05$, graph) and D_{av} and eigenvalues decreased significantly with age ($p<0.05$).

Discussion: This study demonstrates the feasibility of using in-vivo HARDI to discriminate complex white matter architecture in infants within a reasonable exam time. As in adults, the motor tract intersects other white matter tracts in the centrum semiovale and q-ball fiber tractography is necessary to traverse these regions. For infants, it is important to estimate the uncertainty in the orientation of the q-ball ODF because of high water content, low anisotropy, and limited SNR due to scanning constraints. The probabilistic q-ball tractography algorithm estimates the fiber orientation uncertainty with the residual bootstrap and was capable of delineating the motor pathway in each case. The tract-specific measurements exhibited the expected age-related trends. Further work with these pediatric HARDI techniques will enable a more detailed analysis of normal and abnormal white matter architecture.

References:

- 1) Tuch D. Magn Reson Med. 2004;52(6):1358-72.
- 2) Hess C., et al. Magn Reson Med. 2006;56(1):104-17.
- 3) Berman J.I., et al. NeuroImage. 2008;39(1):215-222.

Acknowledgement: NIH 5P50NS35902, 1R01EB009756, 1R01S046432

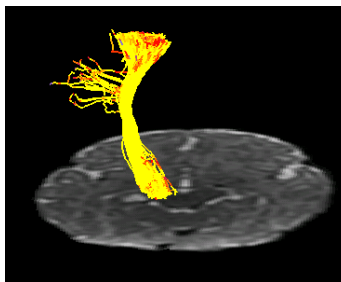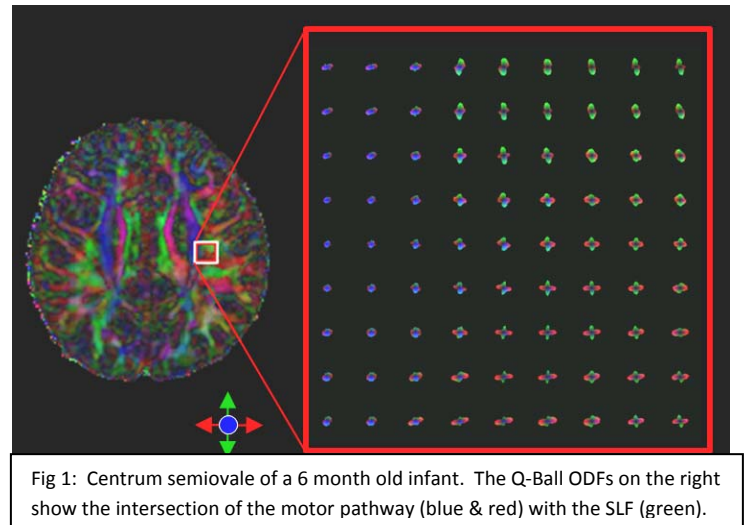


Fig 2: Coronal 3D view of the left motor pathway in a 3 month old. Connectivity is seen between a large portion of the motor cortex and the midbrain.

