

## Deformation based morphometry (DBM) in temporal lobe epilepsy with and without mesial temporal sclerosis

C. Scanlon<sup>1</sup>, S. G. Mueller<sup>1</sup>, D. Tosun<sup>1</sup>, I. Cheong<sup>1</sup>, M. W. Weiner<sup>1</sup>, and K. D. Laxer<sup>2</sup>

<sup>1</sup>Center for Imaging of Neurodegenerative Diseases, Dept. of Radiology and Biomedical Imaging, University of California, San Francisco, California, United States,

<sup>2</sup>Pacific Epilepsy Program, California Pacific Medical Center, San Francisco, California, United States

**Background:** Patients suffering from non-lesional medial temporal lobe epilepsy can, based on the appearance of the hippocampus, be divided into 2 clinical sub-groups: TLE with mesial temporal sclerosis as defined by MRI (TLE-mts), and those with normal appearing MRI on visual inspection (TLE-no). Structural MRI studies have consistently demonstrated global volumetric changes in TLE-mts. Structural changes in TLE-no are more subtle and have mainly been demonstrated using ROI methods of the mesial temporal structures. Deformation based morphometry (DBM) non-linearly transforms brain images to a standard template and maximizes the alignment of the anatomies between the individual brain and the template. The anatomical differences then lie in the deformation fields that are required to transform the subjects' brain. The aim of this study was to identify structural shape changes using DBM in both TLE-mts and TLE-no.

**Methods:** 15 TLE-mts (9 left, 6 right onset), 14 TLE-no (7 left, 7 right onset) and 33 controls were included in this study. MR images of right onset patients were right-left flipped so the ipsilateral hemisphere was on the left in all cases. Flipped and un-flipped control subject MR images were also included. A symmetrical unbiased template brain was constructed from 35 control subjects (both original and sided flipped) [1]. Subjects were initially affine transformed, followed by a fluid flow deformation used to register each subject brain to the template [1]. Jacobian determinants were calculated from the derived deformation field and the resulting maps were smoothed by a 4mm full-width-at-half-maximum Gaussian kernel. Voxel-wise analysis was carried out between patient and control groups in SPM2 using an ANCOVA model with age as a nuisance variable. T-statistic maps between patient and control groups were corrected for multiple comparisons with a false discovery rate (FDR) of  $p < 0.05$ .

**Results:** Compared with controls, TLE-mts patients showed significant atrophy in the ipsilateral hippocampus (as expected), parahippocampal gyrus, bilateral thalamus, putamen, caudate, brain stem and cerebellum. Significant regions of atrophy in TLE-no were found in the ipsilateral temporal lobe, more specifically the parahippocampal gyrus, fusiform and superior temporal gyrus. Further atrophy was found in the bilateral superior frontal cortex, brain stem and cerebellum (Figure 1). Apart from some overlap in the cerebellum and parahippocampal gyrus, the distributions of findings differ between the 2 subgroups.

**Discussion:** DBM showed significant volume losses in TLE-mts that are consistent with previous voxel-based morphometry (VBM) studies. Significant although less prominent volume losses were demonstrated in TLE-no. A major finding of this study was that the spatial distribution of volume losses was different between the two TLE subgroups. These results suggest that TLE-no is a different disorder from TLE-mts and is not simply a milder form of TLE-mts as has been often suggested. Finally, the fact that previously reported findings of voxel-based studies in TLE-no did not survive such a stringent multiple comparison correction as in our study, provides evidence that DBM may be a more sensitive technique than VBM to pick up the subtle volume changes associated with TLE-no.

### References:

[1] Lorenzen P, Prastawa M, Davis B, Gerig G, Bullitt E, Joshi S. Multi-modal image set registration and atlas formation. *Med Image Anal.* 2006;10:440-51.

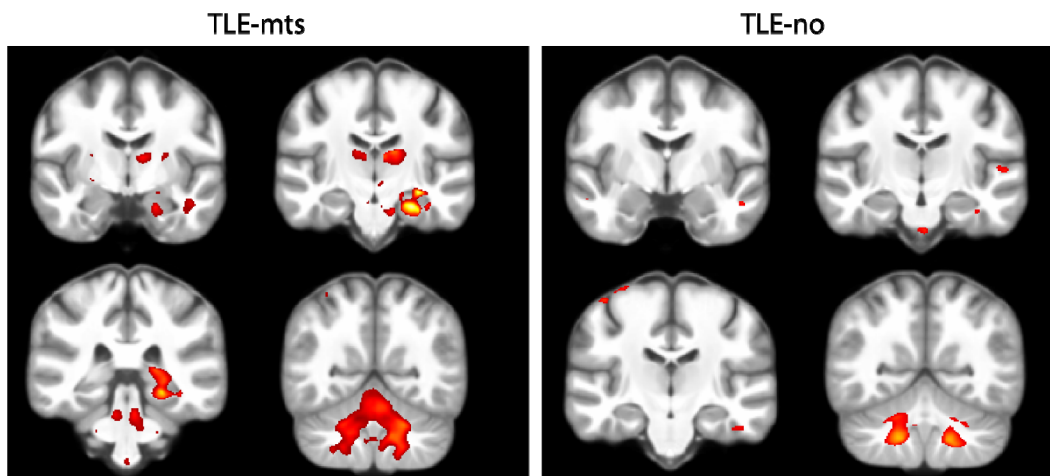


Figure 1. Coronal slices demonstrating significant regions of abnormality in TLE-mts and TLE-no