

ADVANCED MR IMAGING OF ACTIVE DUTY MILITARY PERSONNEL FOLLOWING ACUTE BLAST-RELATED TBI

C. L. MacDonald¹, D. Cooper¹, J. Witherow², A. Snyder³, J. Shimony³, M. Raichle³, S. Flaherty², R. Fang², and D. Brody¹

¹Neurology, Washington University, Saint Louis, Missouri, United States, ²Landstuhl Regional Medical Center, Landstuhl, Germany, ³Radiological Sciences, Washington University, Saint Louis, Missouri, United States

Introduction: Military personnel have a higher rate than civilians of Traumatic Brain Injury (TBI) even during times of peace. TBI has been called the signature injury of the wars in Iraq and Afghanistan. Many of these injuries occur as the result of blast exposure, but little is known about the characteristics of blast-related TBI. Diffusion tensor imaging (DTI) was employed for this study of active duty military personnel. DTI has shown promise as a potential diagnostic tool in the evaluation of traumatic axonal injury (Mac Donald et al, *Exp Neurol*, 2007; Mac Donald et al, *J Neurosci*, 2007) but it has not been used to characterize acute blast-related TBI. For this study, 20 controls exposed to blast but free of any signs or symptoms of TBI and 43 subjects exposed to blast evaluated as positive for TBI were scanned acutely after injury at Landstuhl Regional Medical Center (LRMC) in Landstuhl, Germany using this advanced MRI method. LRMC is the primary tertiary hospital serving OIF and OEF theatres; nearly all seriously injured US military personnel are evaluated there for decisions regarding return to duty or transport back to the United States. Thus, recruiting subjects at LRMC allows evaluation of a relatively unbiased cohort of acutely injured personnel.

Methods: Active-duty service members were scanned on a 1.5T Avanto MRI scanner (Siemens, Erlangen, Germany). Following the methods of Shimony et al, (*Cereb Cortex*, 2006), patients were scanned with 25 direction DTI (TR=10200ms, TE=102ms, 2.5 x 2.5 x 2.5 mm voxels). Standard anatomical scans (MPRAGE, T2-weighted fast spin echo, and FLAIR) were also employed. All service members were male, ages 19-49 yrs (median 25 yrs), ranging 1-90 days post injury (median 17 days). Post-processing was performed to align each set of scans into standardized Talairach coordinate system using cross modal affine transformations. DTI parameters (relative anisotropy, axial diffusivity, and radial diffusivity, and apparent diffusion coefficient) were analyzed in 11 regions of white matter across multiples slices encompassing the entire white matter tract of interest for each subject and compared to controls. These regions included the genu, body and splenium of the corpus callosum, left and right anterior as well as posterior internal capsule as well as the left and right cingulum and left and right uncinate fasciculus.

Results: Of the 43 blast-related TBI subjects only 3 had abnormal readings on the conventional images as evaluated by a clinical radiologist (J. Witherow). Reductions in anisotropy were noted in regions appearing normal on the standard anatomical scans. For example, the anisotropy within the uncinate fasciculus was significantly changed following blast-TBI a significant number of service members (Figure: top). The red line indicates what would statistically be expected by chance for the group size. In the blast-TBI patients there were large numbers of abnormal regions of interest across DTI metrics (Figure: bottom). Regional abnormality was defined as a signal within a region at least two standard deviations

away from the mean of the controls.

Discussion: The results of this study demonstrate that it is feasible to acquire MRI data acutely in active duty service members and highlight the additional information gained by this advanced MRI method. If routinely acquired, this information has the potential to dramatically advance the assessment and triage of injured US active duty military personnel.

Support: Department of Defense grant PT075299 (D. Brody), F32 NS 062529 – 01 (C. Mac Donald) & the Washington University NeuroImaging Lab.

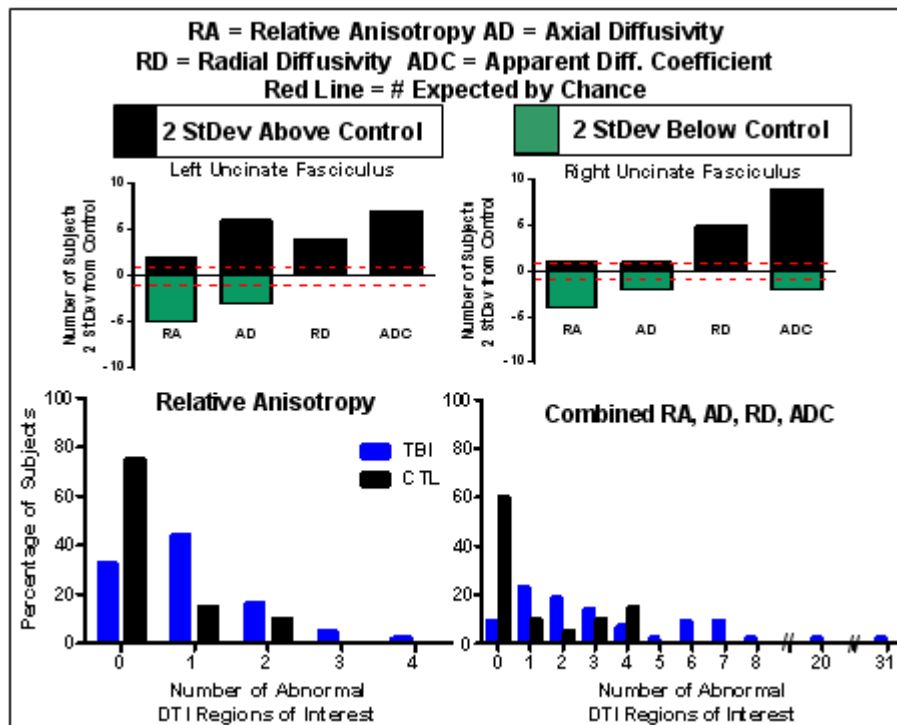


Figure 1. DTI abnormalities in blast-TBI subjects vs. Control. (top) Number of blast-TBI subjects with abnormalities in a specific region (uncinate fasciculus) relative to what would be expected by chance for the sample size (bottom). Percentage of subjects in both groups with abnormalities 2 standard deviations from mean control across regions of interest. Note the increased number of blast-TBI subjects with large numbers of abnormalities.