

A Study of APOE and Cerebral Perfusion in Adult Offspring of Patients with Alzheimer's Dementia using Dynamic Susceptibility Contrast MRI

R. D. McKinsey¹, Z. Wen¹, A. McMillian¹, B. Meyerand¹, S. Johnson², S. Fain^{1,3}, and C. Carlsson²

¹Medical Physics, University of Wisconsin-Madison, Madison, WI, United States, ²GRECC, Veteran Administration Hospital, Madison, WI, United States, ³Radiology, University of Wisconsin-Madison, Madison, WI, United States

Introduction

Alzheimer's Disease (AD) is the most common neurodegenerative disease with an irreversible cognitive decline. It has been shown that Apolipoprotein E (APOE) and vascular dysfunction are associated with increased risk of AD¹. Changes in perfusion have been identified in APOE carriers versus non carriers².

Blood flow is a candidate marker for detecting early stages of AD because a decrease in cerebral perfusion has already been observed with perfusion MRI in AD using Arterial Spin labeling (ASL) techniques³. However, the ASL perfusion method does not provide complementary information on blood volume and transit time that can help distinguish reduced perfusion due to brain atrophy from vasoregulatory changes. The application of DSC perfusion with intravenous gadolinium contrast injection to investigate perfusion changes in AD has the ability to provide cerebral blood flow (CBF), cerebral blood volume (CBV), and mean transit time (MTT) perfusion maps. Also this technique can be performed rapidly and is less sensitive to normal age-dependent reductions in blood flow. The purpose of this study is to investigate the ability of DSC MRI to measure CBV, CBF, and MTT changes in non-demented children with increased risk for AD due to one or more risk factors: APOE and/or family history.

Materials and Methods

Thirty one middle-aged adult children of persons with AD, 19 non-ApoE carriers and 12 ApoE carriers were scanned on a GE Signa 1.5 T MR. The perfusion imaging protocol included two injections, one rapid bolus and one slow infusion of contrast agent (gadolinium). Multiple blocks of single shot EPI images were acquired with TE of 35 msec and 128x64 matrix. The bolus injection was delivered 65 $\mu\text{mol/kg}$ of gadodiamide (Ominscan®, Nycomed, NY) for 3 sec using MR compatible injector (Medrad, Inc., Indiana, PA) with a TR of 1150 msec. The infusion injection is delivered 1.6 $\mu\text{mol/kg/sec}$ with a TR of 3000 msec. The total Gd dose did not exceed the FDA limit of 300 $\mu\text{mol/kg}$.

Parametric maps were generated using SPM8 and compared for ApoE negative and ApoE positive groups for differences in CBV, CBF, and MTT. The perfusion maps were calculated by first selecting the arterial input function (AIF) followed by deconvolution with block-circulant SVD⁴. The CBF map was generated using the central volume principal, $\text{CBF} = \text{CBV}/\text{MTT}$. The CBV was derived from the infusion scan while the MTT was derived from the bolus scan. The DARTEL suite within SPM8 [The Wellcome Department of Imaging Neuroscience, London, UK] was used to generate a customized template from the input patient population to achieve more accurate inter-subject registration⁵. The transformation, flow field, derived from the previous step was used to register the perfusion maps into DARTEL Space. The DARTEL Template along with the CBV, CBF, MTT maps were normalized to MNI Space using an external shell script and smoothed with a 10mm FWHM Gaussian kernel. A two-sample t-test was implemented voxel by voxel with a significance threshold of $p < 0.01$.

All subjects had a cognitive battery of testing including, CSF levels of β -amyloid, cholesterol levels, blood pressure, education, exercise history, and smoking to name a few. The protocol includes an MR scan, placement on a placebo or simvastatin, and second MR scan.

Results

A decrease in perfusion is observed in expected areas for AD including early Alzheimer's. The statistics maps generated showed differences in CBF, MTT, and CBV for APOE negative and APOE positive groups. (Results are displayed on the generated DARTEL Template 6 normalized to MNI space for APOE positive.) Locations of maxima are reported in units of mm. Figure 1 showed decreased CBF in the temporoparietal (border b/t temporal and parietal lobe), $T\text{value} = 2.47$ (-36, -60, 25). Figure 2 shows a decrease in the MTT located in the insula $T\text{value} = 3.42$ (-53, -5, 9). Figure 3 shows a decrease in CBV for in the inferior temporal gyrus $T\text{value} = 2.47$ (49, -58, 7).

We have found differences in perfusion measures which suggest that decreased perfusion could be a very early indicator of AD. These findings support the results of person's with increased risk for AD due to family history. This population shows preclinical brain differences compared to non-carriers.

Discussion

These data support the results of person's with increased risk for AD due to family history. This population shows preclinical brain differences compared to non-carriers. PET findings have indicated the temporoparietal is associated with early AD. Future directions will include a family history negative comparison group to isolate the effects of family history on the brain. Longitudinal studies are needed to see if regionally decreased perfusion predicts later development of AD. A perfusion technique should be developed for early detection of AD. Limitations include uncorrected p-value. For CBV, decrease in right insula in AD has been observed in early AD using brain perfusion SPECT

References

1. Chapman, J et al. Stroke 29:1401-1404 (1998).
2. Fleisher, AS et al. Alzheimer's Dementia 2:S671-S672 (2006).
3. Johnson NA et al. Radiology 234:851-859 (2005).
4. Newman GC et al. AM J Neuroradiology 27:1239-40-2 (2006).
5. Ashburner, J. NeuroImage 38:95-113 (2007).

Acknowledgements

NINDS 1F31NS52971-01, NIA R01 AG2155, and by a Merit Review grant from the Department of Veterans Affairs

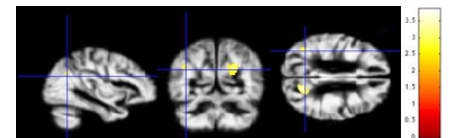


Fig 1. Statistical Parametric Maps of reduced cerebral blood flow in APOE positive ($p < 0.01$). Color bar indicates T-statistic.

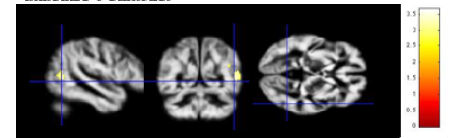


Fig 2. Statistical Parametric Maps of reduced mean transit time in APOE positive ($p < 0.01$). Color bar indicates T-statistic.

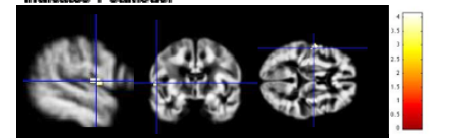


Fig 3. Statistical Parametric Maps of reduced cerebral blood volume in APOE positive ($p < 0.01$). Color bar indicates T-statistic.