

T. Yoshiura¹, A. Hiwatashi¹, K. Yamashita¹, H. Kamano¹, Y. Takayama¹, E. Nagao¹, T. Dashjamts¹, and H. Honda¹

¹Department of Clinical Radiology, Kyushu University, Fukuoka, Japan

Introduction

It has been documented that Alzheimer’s disease (AD) is associated with degeneration of cerebral subcortical white matter (subcortical WM), which is likely secondary to degeneration of overlying cerebral cortex. Such degeneration in subcortical WM is manifested as increased local water molecular diffusivity in diffusion-weighted (DW) imaging. Analysis of degrees and topographical patterns of abnormalities in the diffusivities within subcortical WM may be of diagnostic values for AD. In this study, we measured diffusivities in subcortical WM in different cortical regions using an atlas-based automated mapping method. We tested our hypotheses that AD is associated with diffusion abnormality in subcortical WM in specific cortical regions and that the degree and topographical pattern of the diffusion abnormalities can be used to diagnose AD.

Materials and Methods

This study involved 33 AD patients (M/F=10/23, 70.6±9.2 years old, range of MMSE score = 10-27, mean = 20.5±4.5) and 28 healthy control subjects (M/F=9/19, 69.1±7.1 years old). Among the AD patients, there were 17 patients with mild AD (MMSE score ≥ 22) (mean MMSE = 24.2±1.9). For each subject, DW images were obtained at a 1.5 T MR imager using a DTI sequence with a CSF-nulling inversion pulse: TR/TE/TI=9200ms/116ms/2300ms, b-value=800s/mm², 6 diffusion-encoding directions, FOV=230mm, matrix size=128x128, number of averages=4. Voxels in subcortical WM were defined using a previously reported method (reference 1). Then mean MD values in the subcortical WM voxels were measured within 78 cortical regions (39 regions in each hemisphere) defined in individual brains according to an anatomically labeled brain atlas (automated anatomical labeling or AAL), and were compared between the AD and control groups (Mann-Whitney U test). In addition, performances of the subcortical WM MD values in discrimination between the two groups were evaluated using uni- and multi-variate analyses. The uni-variate analysis was based on the subcortical MD values within a region where the highest significance of the difference between the two groups was observed. For the multi-variate analysis, a linear discriminant analysis was used to generate a multi-variate model based on the regional MD values for discrimination. Step-wise selections of the variables were used at p value thresholds for entry and stay of < 0.05, respectively.

Results

In AD patients, mean MD values in subcortical WM were elevated compared to those of control subjects in all cortical regions but the bilateral postcentral gyri, bilateral paracentral lobules and right SMA (Fig.1-LEFT). Significant elevation was found in 29 cortical regions in the frontal, parietal, temporal and occipital lobes (Fig.1-RIGHT). Uni-variate discriminant analysis based on MD in the left middle occipital gyrus, where highest significance of MD difference was observed resulted in the accuracy of 88.5 % and AUC value in ROC analysis of 0.939 (Fig.2). Multi-variate analysis resulted in the accuracy of 96.7 % and AUC value of 0.997 (Fig.2). A high accuracy was demonstrated even when mild AD patients were discriminated from the control subjects (accuracy=97.8%).

Conclusion

Using an automated method, we revealed region-specific diffusion abnormalities in subcortical WM in AD patients. We also demonstrated that the degrees and the topographical pattern of the abnormalities in subcortical WM diffusivity can be used to discriminate AD patients from healthy subjects, suggesting the diagnostic value of this analysis method.

References

1. Yoshiura T, et al. Magn Reson Med 2005;54(2):455-9.

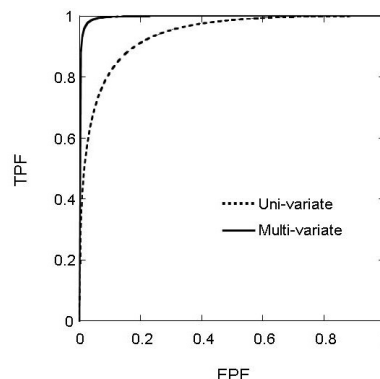
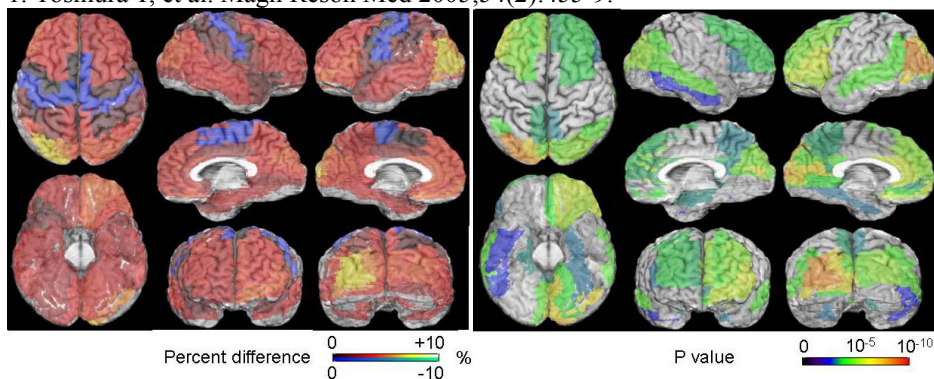


Fig. 1: Mapping of percent difference (LEFT) shows that mean MD values in subcortical WM are diffusely elevated in AD patients compared to healthy subjects in all cortical regions except for the bilateral pericentral regions and SMAs. Significant MD elevations are observed in 29 cortical regions (RIGHT).

Fig. 2: ROC results for discriminant analyses. The AUC value for the uni-variate analysis was 0.939, while that for multi-variate analysis was 0.997.