

Diffusion Tensor Imaging at 7 Tesla as a Probe of Uterine Fibroid Morphology

M. J. Thrippleton¹, K. I. Munro¹, M. E. Bastin², M. A. Jansen², G. D. Merrifield², S. I. Semple³, A. Oniscu¹, A. W. Horne¹, A. R. Williams¹, G. McKillop⁴, I. Marshall², D. E. Newby^{3,5}, and H. O. Critchley¹

¹Centre for Reproductive Biology, University of Edinburgh, Edinburgh, Lothian, United Kingdom, ²Department of Medical Physics, University of Edinburgh, ³Clinical Research Imaging Centre, University of Edinburgh, ⁴Department of Radiology, Royal Infirmary of Edinburgh, ⁵Centre for Cardiovascular Science, University of Edinburgh

Introduction

Uterine fibroids are benign growths of uterine muscle, present in up to 70% of women of reproductive age. Although many women with fibroids are asymptomatic, others experience heavy menstrual bleeding, abdominal discomfort, pressure-related bladder symptoms and subfertility. We are developing MR biomarkers for assessing the mechanism and effectiveness of new medical treatments. In this abstract, we describe the results of development work aimed at probing the water diffusion properties of the *ex-vivo* fibroid uterus at 7 T; we measure the water diffusion parameters of fibroid tissue subtypes and compare diffusion eigenvector maps with macroscopic tissue appearance.

Methods

Ethical approval was obtained. 8 women (48-61 years) with symptomatic fibroids and scheduled for hysterectomy were studied. After hysterectomy, *ex-vivo* MR images were acquired using a Varian 7 T pre-clinical scanner equipped with a 200 mT m⁻¹ gradient coil and 150 mm quadrature radiofrequency volume resonator coil. A fast spin-echo sequence (slice thickness = 2 mm, FOV = 200 × 200 mm, echo train length = 4, 1 average) was employed. High resolution T2-weighted images were acquired (TR/TE = 4500–5410/56 ms, matrix size = 512 × 512); diffusion tensor MRI (DT-MRI) was also performed with diffusion-weighting gradients applied in 12 directions (TR/TE = 3035–6422/26 ms, matrix size = 128 × 128, $b_{\text{eff}} = 915 \text{ s mm}^{-2}$) and two scans without diffusion weighting. The uteri were then fixed, sectioned and photographed by a pathologist in the same plane as the MR acquisition. Fractional anisotropy (FA) and mean diffusivity (MD) maps were constructed from DT-MRI data, as well as principal eigenvector maps showing the direction of greatest diffusion for each voxel. Regions of interest based on macroscopic tissue appearance (including normal fibroid tissue, degenerating fibroid and fibroid-myometrium interface) were selected, and mean FA and MD values were measured; differences in parameters were analysed according to tissue type.

Results

Principal eigenvector maps qualitatively reproduce the macroscopic appearance of the photographed tissue sections (Figure 1). Principal eigenvectors close to the interface between fibroid and myometrium run parallel to the interface, and an anisotropic periphery is present on FA maps. Mean FA was lower in regions of myxoid degeneration (0.186 ± 0.039 , $n = 5$)[†] and higher at the myometrium-fibroid interface (0.350 ± 0.038 , $n = 8$), compared with normal fibroid regions (0.278 ± 0.048 , $n = 23$); mean MD was higher in myxoid regions ($0.00173 \pm 0.00053 \text{ mm}^2 \text{ s}^{-1}$) compared with normal fibroid tissue ($0.00107 \pm 0.00019 \text{ mm}^2 \text{ s}^{-1}$).

[†] mean ± SD; $P < 0.05$

Discussion

These pilot data demonstrate the promise of probing fibroid tissue morphology by DT-MRI. Principal eigenvector maps reproduce the patterns of competing smooth muscle whorls observed in tissue sections, though correspondence is limited by the precision with which tissue can be sectioned. Increased FA and orientation of principal eigenvectors at the fibroid-myometrium interface are consistent with the compression effects of fibroids, and the observed FA reduction in myxoid tissue is consistent with the loss of connective tissue associated with this form of degeneration. We note that Weiss *et al.* have previously reported DT-MRI data relating to a single fibroid uterus at 3 T [1]. Histochemical staining is currently in progress, so that water diffusion parameters can be correlated to specific tissue components, including smooth muscle and collagen. We will also perform *in-vivo* uterine DT-MRI for development as a clinical biomarker for treatment response.

References

[1] Weiss S. *et al.*, *Anat Rec A*, 2006, 288A:84–90.

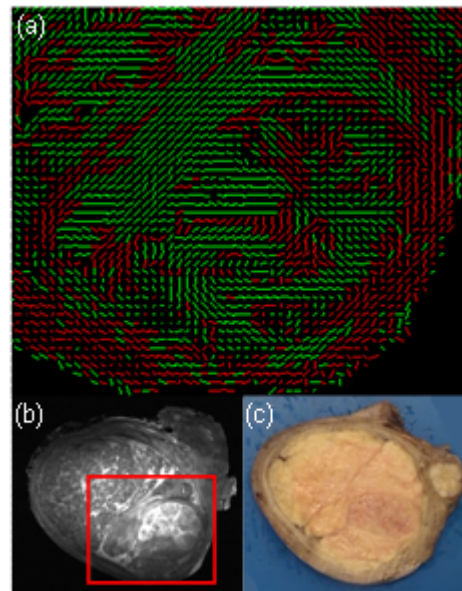


Figure 1. Slice from fibroid uterus: (a) orientations of principal diffusion eigenvector (green/red colouring denotes a prolate/oblate DT ellipsoid); (b) T2W image; red box denotes enlarged region covered by eigenvector map; (c) macroscopic photograph.