

CSF Contamination Correction in DTI Tractography of the Fornix in Elderly Subjects

S. Tsao¹, D. H. Hwang¹, and M. Singh^{1,2}

¹Department of Biomedical Engineering, University of Southern California, Los Angeles, CA, United States, ²Department of Radiology, University of Southern California, Los Angeles, CA, United States

Introduction:

The microstructural integrity of the limbic regions is frequently compromised in neurodegenerative diseases such as Alzheimer Disease (AD). A key limbic region is the fornix located proximal to the ventricles. Given the relatively large voxel size used in most clinical DTI acquisitions, the probability of CSF contamination in the fornix is high, often leading to interruption of tracts due to either a reduction in FA or misdirection due to erroneous eigenvector estimation, particularly in AD where ventricles are enlarged. FLAIR DTI has been used by many investigators to suppress CSF (e.g. Kwong et al. MRM 21, 157-163, 1991) but at the expense of SNR and data acquisition time, and to our knowledge, FLAIR DTI is rarely used in clinical studies. Aiming toward eventual quantification of DTI metrics such as FA and tract density in the fornix and other limbic pathways in AD, the objective of this work was to develop a post-processing strategy to correct partial volume effects such that it could be used to analyze existing clinical DTI data.

Methods:

Existing DTI data acquired on a 3T GE Signa HDx MRI using a multi-slice, twice refocused sequence with 128x128 single-shot EPI readout, 25 gradient directions with $b=1000s/mm^2$, one $b=0$ image, TR/TE=8000ms/86.1ms, FOV 26cm, two averages, 4mm thick contiguous 28 slices covering the entire head in $2.03 \times 2.03 \times 4 \text{ mm}^3$ voxels (scan time: approximately 7 minutes) were used. Relying on a straightforward bi-compartmental model (e.g., Koo et al. NeuroImage 44:136-144, 2009) $S = f_{WM}S_{WM} + f_{CSF}S_{CSF}$, where S_{CSF} , S_{WM} are the signals from a pure CSF and white matter (WM) voxel and f_{CSF} , f_{WM} are corresponding fractions of CSF and WM. We can isolate the white matter signal within any particular voxel by extending this model to the DTI signal for the 25 gradient directions given by $\frac{S^i}{S_0} = \frac{f_{WM}S_{WM}^i + f_{CSF}S_{CSF}^i}{f_{WM}S_{0WM}^i + f_{CSF}S_{0CSF}^i}$.

This allows us to extract the WM only DTI signal given by $\frac{S_{WM}^i}{S_{0WM}^i} = \frac{S - f_{CSF}S_{CSF}^i}{S_0 - f_{CSF}S_{0CSF}^i}$. As we are only concerned with the mixing between CSF and white matter in this study, the gray matter (GM) fraction has been ignored but can be readily incorporated in a three-compartmental model.

Derivation of f_{CSF} was based on using MD values of the voxel. K-means clustering was used to separate all voxels into three clusters: CSF, WM and GM. A linear interpolation was done between the CSF and the WM MD values as an estimate of CSF content. To get S_{CSF} and S_{0CSF} , we used only the voxels from the ventricles and with CSF content f_{CSF} greater than 99%. Correction was then performed only on voxels with f_{CSF} less than 70 percent to avoid problems with overcompensation and possible errors in our estimate of f_{CSF} .

Results:

An increase in FA was found in tract-based ROIs of the fornix after correction, due to an increase in anisotropy after the isotropic CSF component has been removed (see table 1). Results also indicate that the primary eigenvector and therefore the tractographic vector orientation can also be corrected (see fig. 1), leading to less erroneous tracts and allowing for the tractography of fornix at a lower FA threshold (see fig. 2).

Discussion and Conclusion:

Our results suggest that WM voxels that have been contaminated by CSF can be corrected via a simple compartmental model that boosts FA values (table 1) and corrects for primary eigenvector orientation estimation (fig. 1). This is particularly useful in aged subjects that have high degrees of cerebral atrophy that increases CSF contamination in a large number of voxels.




Figure 1 - Corrected Primary Eigenvectors after CSF compensation correction in the anterior portion of the Fornix (Red - Original Eigenvector) (Green - Corrected Eigenvector)

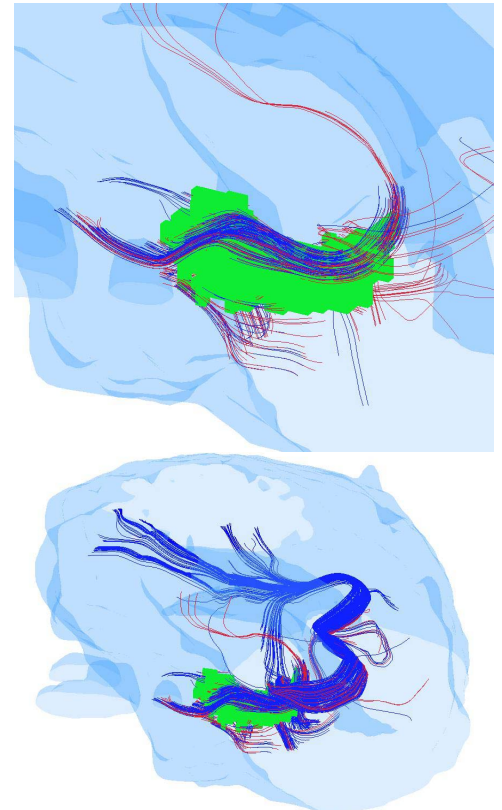


Figure 2 - Corrected Tractography (RED) and uncorrected Tractography (BLUE) at FA threshold of 0.14 of tracts of the Hippocampus (green ROI). Figure shows (1) correction recovering the superior portion of the fornix (2) reduction of erroneous tract.

Subject	Right Fornix		Left Fornix	
	Corrected FA	Original FA	Corrected FA	Original FA
1	0.4150 ± 0.0372	0.3398 ± 0.0219	0.4428 ± 0.0312	0.3633 ± 0.0210
2	0.2149 ± 0.0182	0.1980 ± 0.0096	0.2801 ± 0.0355	0.2465 ± 0.0170
3	0.2179 ± 0.0344	0.1884 ± 0.0133	0.1997 ± 0.0094	0.1968 ± 0.0058
4	0.2476 ± 0.0370	0.2010 ± 0.0147	0.3175 ± 0.0405	0.2627 ± 0.0227

Table 1 - Corrected FA scores of 4 Normal age matched elderly subjects