

Segmentation of Ischemic Lesion from Diffusion Weighted MRI and MR Apparent Diffusion Coefficient Maps

Y. attal¹, C. Rosso², Y. Samson², and S. Baillet³

¹CRICM - CNRS UMR7225, Paris, France, Metropolitan, ²AP-HP-Urgences Cérébro-Vasculaires, Paris, France, Metropolitan, ³MEG Program, Department of Neurology, Medical College of Wisconsin-Froedtert Hospital, Milwaukee, US

Introduction

The utility of diffusion-weighted MRI (DWI) in the assessment of acute ischemic stroke is now becoming well-established. The quantitative evaluation of the lesion is however problematic because of the lower resolution of clinical images in the context of extreme emergency. We have developed a new segmentation technique to extract the ischemic areas from standard, clinical DWI image volumes. Though apparent diffusion coefficient (ADC) maps generated from DWI at several b values provide quantitative information within the ischemic infarct core [1-2], they show poorer contrast between the infarct and healthy/penumbra tissues than the initial DWI data. Here, we combined ADC with DWI data to achieve the automatic extraction of the lesion core.

Materials and methods

Patient data (N=40) with acute middle cerebral artery (MCA) stroke symptoms were selected from the La Salpêtrière stroke center (Paris, France) database. The patients were MR-scanned within the first 6 hours following symptoms onset (delay: mean = 2.6 hours, range [1.5, 4.8]). The database was split in two subgroups. The first group (N=20) was used to adjust the model parameters necessary to the segmentation; the second group of 20 patients was used for generalization/validation. DWI image sequences yielded series of 256x256 axial scans (5-mm thickness, spin-echo multi-slice single-shot echoplanar imaging) with a baseline T2 acquisition ($b=0 \text{ s.mm}^{-2}$) and $b=1000 \text{ s.mm}^{-2}$. ADC maps were generated with a dedicated software tool (FuncTool, General Electric, Buc, France). Initial lesion ROIs were manually delineated by a neurologist for quantitative comparison with the automatic segmentation. This latter consisted of 4 steps.

- 1) ADC maps were thresholded between 150 and $1200 \cdot 10^{-6} \text{ mm}^2\text{s}^{-1}$ to remove voxels contaminated by partial volume effects from cerebrospinal fluid. The core of the lesion was initially extracted from ADC maps with a threshold set between 150 and $500 \cdot 10^{-6} \text{ mm}^2\text{s}^{-1}$. Contrast enhancement was performed using DWI sequences.
- 2) Segmentation of the DWI image volume in multiple classes (air, white/grey matter, infarct (INF)) was achieved using an Expectation–Maximisation (EM) technique assuming that the conditional distribution of voxel grey levels for each class had the same intensity value for all voxels of a given tissue class, corrupted by a normally-distributed additive noise. Morphological post-processing was performed using erosion and dilatation of the masks to remove spurious segmentation artefacts.
- 3) ADC mask and INF mask were labelled in 3D, yielding volume blobs.
- 4) ADC blobs and INF blobs were matched to identify the blobs belonging to the infarct region.

Results and conclusions

The infarct volumes estimated from this technique were found to match those obtained from the expert's manual segmentation (see figures below). We have found that this technique addressed satisfactorily some limitations raised in previous publications (see [3-4]), most notably in the segmentation of smaller ischemic lesions. The technique is fast and took about 1 minute on average per segmentation on a conventional laptop computer (CPU Intel 2.10 GHz, 4Go DDR2 RAM).

To conclude, we developed a fast and robust method to automatically segment ischemic lesions from a combination of acute diffusion-weighted MRI and apparent diffusion coefficient image volumes.

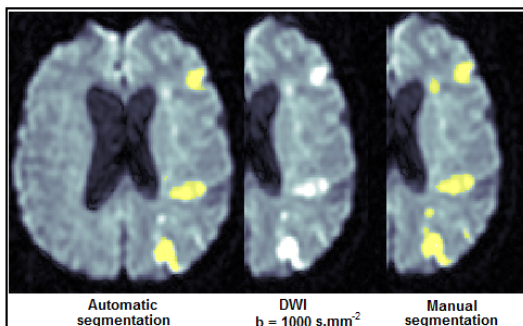


Figure 1: An example of the automatic segmentation on the left and the manual segmentation on the right

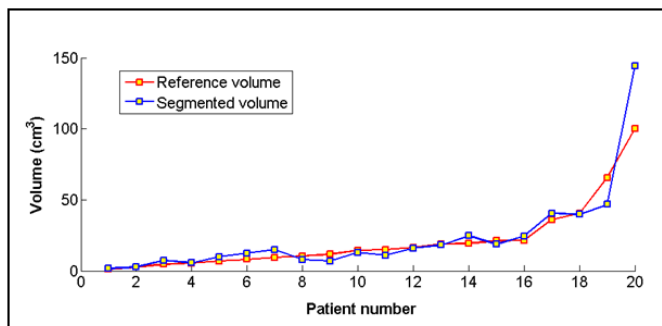


Figure 2: Volumes of the infarct lesions manually delineated by the neurologist (Reference volume) and segmented by the algorithm proposed (Segmented volume)

References

- [1] C. Oppenheim, et al, "Prediction of malignant middle cerebral artery infarction by diffusion-weighted imaging," *Stroke*, vol. 31, pp. 2175–2181, 2000.
- [2] D. G. Na, et al, "Diffusion – weighted MR imaging in acute ischemia value of apparent diffusion coefficient and signal intensity thresholds in predicting tissue at risk and final infarct size," *AJNR Am. J. Neuroradiol.*, vol. 25, no. 8, pp. 1336–2004, 2004.
- [3] A. L. Martel, et al, "Measurement of infarct volume in stroke patients using adaptive segmentation of diffusion weighted MR images," *Medical Image Computing and Computer-Assisted Intervention, MICCAI'99*, vol. 1679, pp. 22–31, 1999.
- [4] B. Stein, et al, "Statistical and Deformable Model Approaches to the Segmentation of MR Imagery and volume Estimation of Stroke Lesions", *MICCAI 2001, LNCS 2208*, pp. 829–836, 2001