

Dynamic contrast-enhanced magnetic resonance for the monitoring of neoadjuvant chemoradiation therapy in rectal adenocarcinoma: initial experience with 20 patients

G. Petralia¹, G. Castellazzi², P. Summers¹, R. Di Filippi¹, M. Pasi², M. G. Zampino³, M. Leonardi⁴, A. Chiappa⁵, S. Viotti¹, L. Bonello¹, and M. Bellomi¹

¹Radiology, Istituto Europeo di Oncologia, Milan, Lombardia, Italy, ²Struttura Complessa di Radiologia/Diagnostica per immagini, Istituto Neurologico IRCCS-Fondazione Casimiro Mondino, Pavia, Lombardia, Italy, ³Medical Care Unit, Department of Medicine, Istituto Europeo di Oncologia, Milan, Lombardia, Italy,

⁴Radiotherapy, Istituto Europeo di Oncologia, Milan, Lombardia, Italy, ⁵General and Laparoscopic Surgery, Istituto Europeo di Oncologia, Milan, Lombardia, Italy

INTRODUCTION: Angiogenesis is a promising target for rectal cancer therapies [1-3], since high values of tumor microvessel density (MVD) [4,5] and high vascular endothelial growth factor expression [6,7] have been correlated with poor outcome [4,5]. An *in-vivo* marker of rectal cancer angiogenesis may therefore be extremely useful for diagnosis, risk stratification, and monitoring of therapeutic success in patients with rectal cancer. The aims of this study were to prospectively monitor with dynamic contrast enhanced magnetic resonance imaging (DCE-MRI) changes in contrast agent pharmacokinetics values in rectal adenocarcinoma over the course of neoadjuvant chemoradiation (NACR) therapy, and to evaluate whether DCE-MRI findings correlate with response to NACR therapy.

METHODS AND MATERIALS: The study was approved by our institutional ethics committee; written informed consent was obtained from all participants before entry into study. Twenty patients (11M, 9F; mean age 61.4 years) with locally advanced rectal non-mucinous adenocarcinoma (T stage \geq T3, or N1-2 as staged by MRI) underwent DCE-MRI before and after NACR therapy, prior to surgery. All exams were performed on a 1.5T Siemens Avanto scanner (Siemens Medical Systems). The parameters for the base sequence for the DCE protocol were 12 slices, TE/TR 1.14/4.36ms, FOV/SLT 360/5mm. Flip angles of 2 and 24° were used for T1 mapping prior to contrast injection. The dynamic acquisition used the above parameters with a flip angle of 24° repeated at 5s intervals for 8 minutes after intravenous injection of (0.2 mL/Kg, 3.5 mL/sec) of contrast agent (Magnevist, Schering, Berlin, Germany), followed by a saline flush.

Regions of interest (ROIs) were drawn by a radiologist on the dynamic time series images with reference to T2-weighted images acquired in the same orientation without access to the pharmacokinetic maps. The tumor was delineated on the 8 central slices of the acquired stack to avoid slab profile effects. Pharmacokinetic modelling followed Tofts model with a default cosine input function calculated voxel-wise using the MRI Workbench software (MRIW, Institute of Cancer Research, Sutton England). For each ROI, the mean, median, standard deviation, and individual voxel values of: transfer constant, K_{trans}; leakage space, V_e; rate constant, K_{ep}; area under the curve, IAUC₆₀ were then extracted. According to the pathologic stage on the surgical specimen, patients were divided in three response groups: those with local downstaging, those with complete response and those who were non-responsive (either no local downstaging or increase in local tumour stage). Differences in the three groups were evaluated by ANOVA. Comparisons were further made for each parameter between the complete response group and the non-responsive group using Student's t-tests and inclusive of all patients between pre- and post-neoadjuvant therapy using paired t-tests.

RESULTS: Examples of k_{trans}, k_{ep}, V_e for the pre- and post-treatment tumor ROIs in one patient are seen in Figure 1. Five patients showed complete response, 11 patients showed local downstaging and 4 patients were non-responsive. ANOVA revealed no inter-group differences for the pre- and post-therapy values, and no changes in values during therapy. T-tests showed significant differences in post-therapy median K_{trans} and IAUC₆₀ and in fractional change of K_{ep} between complete and non-responsive groups ($p < 0.05$). Across all patients (one exemplar seen in Figure 2), the values of K_{trans} and K_{ep} significantly decreased – mainly through reduction of the right (high value) tail, whilst V_e increased significantly ($p < 0.01$) after therapy.

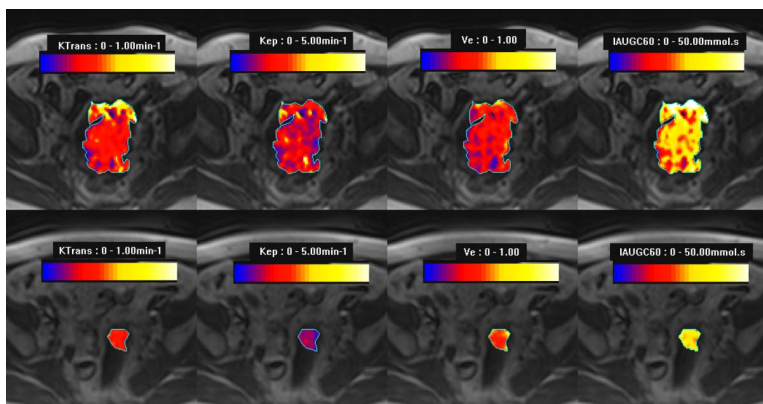


Figure 1 - Colour maps of rectal tumour pharmacokinetic parameter maps before (upper row) and after (lower row) neoadjuvant therapy. From left to right, K_{trans}, K_{ep}, V_e and IAUGC₆₀, each with higher values in hotter colors.

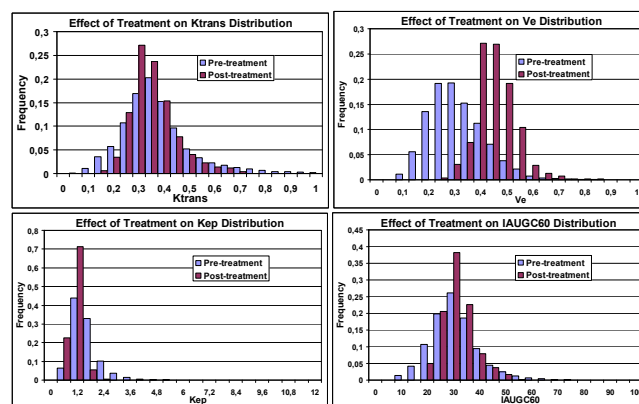


Figure 2 – Histogram distributions for pharmacokinetic parameters before and after neoadjuvant therapy illustrating the effect of therapy: reduction of K_{trans} and K_{ep}, increase of V_e, IAUGC₆₀ tended to reduce in width of distribution.

CONCLUSION: DCE-MRI showed potential for monitoring the effects of NACR therapy in rectal adenocarcinoma as indicated by changes between the pre and post-therapy values, and the distinction between responders and non-responders in the post-therapy period. Between group differences prior to therapy however were not detected amongst the small study population recruited to date.

References:[1] O'Connell MJ. Oncology (Williston Park) 2004;18(6):751–755. [2] Zhu AX. Semin Oncol 2005;32(1):103–112. [3] Hobday TJ. Clin Colorectal Cancer 2005; 5(suppl 1):S11–S18. [4] Takebayashi Y et al. Cancer 1996;78(2):226–231. [5] Li C et al. Br J Cancer 2003;88(9):1424–1431. [6] Cascinu S et al. Br J Cancer 2002;86(5):744–749. [7] Theodoropoulos GE et al. Int J Colorectal Dis 2006;21(3):248–257.