

White Matter Model for Diffusional Kurtosis Imaging

E. Fieremans¹, J. H. Jensen¹, A. Tabesh¹, C. Hu^{1,2}, and J. A. Helpert^{1,2}

¹Radiology, New York University School of Medicine, New York, New York, United States, ²Center for Advanced Brain Imaging, Nathan S. Kline Institute, Orangeburg, New York, United States

Introduction

Diffusional kurtosis imaging (DKI) has been proposed as a clinically feasible extension of DTI to probe the restricted water diffusion in biological tissues [1]. Here we developed an idealized diffusion model of white matter (WM) suitable for DKI analysis, which allows for quantification of the intra- and extra-axonal diffusivities, the axonal water fraction and the tortuosity of the extra-axonal space. This approach provides a more meaningful physical interpretation of DKI metrics for WM.

Theory

Assume WM is composed of parallel axons each surrounded by a myelin sheath with an along axis diffusion coefficient of D_a . We take the perpendicular axon diffusivity to be zero since myelinated axons have a very low permeability and a small radius ($\sim 1\mu\text{m}$). We refer to the remainder of the WM as the extra-axonal space (EAS), and model it as an effective medium with a diffusion coefficient D_e parallel to the axons' axes and a diffusion coefficient D_e/λ perpendicular to the axons' axes, where λ is the tortuosity of the medium. In addition, we indicate the axonal water fraction (AWF), i.e., the volume fraction of water in the axons relative to the total water volume, by the symbol f . Since the protons in myelin do not contribute to the DWI-signal, the system then consists of two non-exchanging compartments. The radial and axial diffusion coefficients, D_{\perp} and D_{\parallel} , and diffusional kurtoses, K_{\perp} and K_{\parallel} , of this two-compartment system are related to the system parameters f , D_a , D_e and λ according to:

$$f = \frac{K_{\perp}}{K_{\perp} + 3}, \quad (1)$$

$$D_{\perp} = D_a \left[1 + \sqrt{\frac{K_{\perp}(1-f)}{3f}} \right], \quad (2)$$

$$D_{\parallel} = D_a \left[1 - \sqrt{\frac{K_{\perp}f}{3(1-f)}} \right], \quad (3)$$

$$\lambda = (1-f) \frac{D_e}{D_{\perp}}. \quad (4)$$

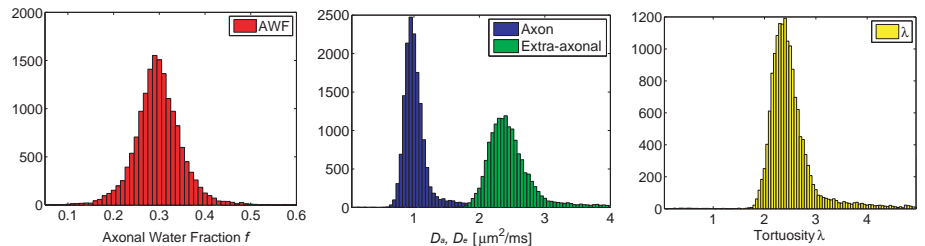


Figure 1: Histograms for the WM parameters

Methods

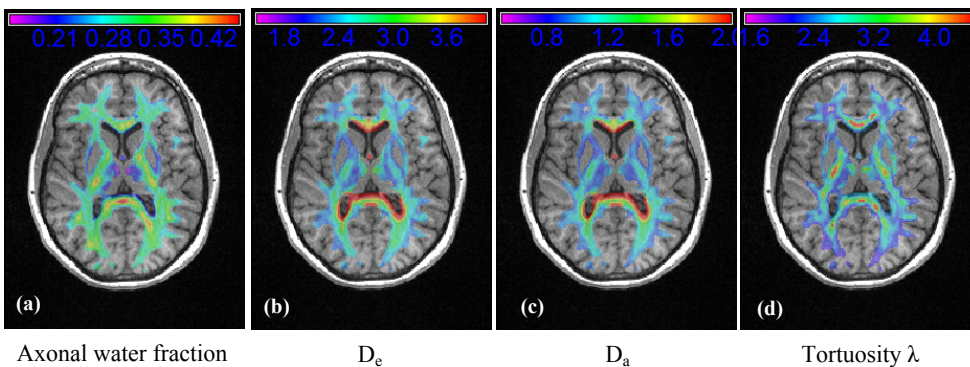
A DKI scan was performed on a healthy 28-year-old female volunteer using a 3 T Siemens Tim Trio system with a 12-channel head coil. Diffusion-weighted images were acquired along 30 gradient directions with a twice-refocused spin-echo planar imaging (EPI) sequence (TR = 5900 ms, TE = 96 ms, matrix = 82×82 , FOV = 222×222 mm², 39 slices, slice thickness = 2.7 mm, no gap, NEX = 11 for $b = 0$, NEX = 2 for $b = 1000, 2000$ s/mm², acquisition time = 13 min.). DTI and DKI parametric maps were calculated using in-house software (Diffusional Kurtosis Estimator (DKE)) running in Matlab. The generated maps for D_{\perp} , D_{\parallel} , K_{\perp} , and K_{\parallel} together with Eqns. (1-4) were then used to derive parametric maps for D_a , D_e , f , and λ .

Results

Histograms for f , D_a , D_e and λ derived from the WM voxels are shown in Figure 1; WM voxels were defined as having a fractional anisotropy (FA) of at least 0.25. The AWF was on average 0.3 ± 0.05 and the tortuosity λ was on average 2.5 ± 0.7 . The average diffusivity of the axons was $D_a = 1.1 \pm 0.3$ $\mu\text{m}^2/\text{ms}$ and the EAS diffusivity was $D_e = 2.6 \pm 0.7$ $\mu\text{m}^2/\text{ms}$. In Figure 2, parametric maps of f , D_a , D_e and λ for one slice are shown as overlays on the MPRAGE.

Discussion

The bare diffusivity in the intra-axonal space is found to be smaller than in the extra-axonal space, and the corresponding mean values for the intra- and extra-axonal bulk diffusivities are in good agreement with the values used in previously considered models for WM [3, 4]. The model presented here allows for quantification of the AWF, which is a measure of the axonal density. The mean AWF of 0.3 obtained using this WM model agrees well with literature values [5]. The tortuosity depends on the water fraction of the EAS and is high in regions with high axonal and myelin density. As an example, the higher values found in the genu and splenium of the corpus callosum for the axonal water fraction and the tortuosity, as shown in Figure 2, can be explained by the high axonal density and the presence of myelin. Using this model for the DKI analysis and more specifically the non-invasive measure of the AWF and the tortuosity could potentially provide important information for assessing neuro-psychiatric and/or neuro-degenerative disorders that may be related to myelin dysfunction, such as Alzheimer's disease [6] and multiple sclerosis [7]. Since a DKI dataset may be acquired within a few minutes, this approach may allow for the clinical assessment of white matter tissue properties.



axonal water fraction

D_e

D_a

Tortuosity λ

Figure 2: Parametric coronal images as overlays on the MPRAGE image: (a) the AWF; (b) the axonal diffusivity D_a ; (c) the extra-axonal diffusivity D_e ; (d) the tortuosity λ . A WM mask (FA > 0.25) was applied to the parametric maps. To correct for subject motion and spatial distortion in the DKI EPI images, the $b = 0$ volume was registered to the subject's skull-stripped MPRAGE using the Automatic Registration Toolbox [2] and the parametric maps were transformed to the subject's MPRAGE volume according to this registration.

References

- [1] J. H. Jensen et al, *Magn. Reson. Med.* **65** (2005):1432-1440.
- [2] <http://www.nitrc.org/projects/art/>
- [3] Assaf et al, *Magn. Reson. Med.* **52** (2004):965-978.
- [4] Sen et al, *Biophys J.* **89** (2005):2927-2938.
- [5] Tang et al, *Neurobiol. Aging* **18** (1997):109-615.
- [6] Bartzokis et al, *Neurobiol. Aging* (2009), doi:10.1016/j.neurobiolaging.2009.08.007.
- [7] Laule et al, *J. Neurol.* **251** (2004):284-293.

Grant support:

- NIH R01AG027852
NIH R01EB007656
Litwin Foundation for Alzheimer's Research