

Accelerating Time-Resolved MRA with Multi-Echo Acquisition

H. J. Jeong¹, C. S. Eddleman², S. Shah³, N. Seiberlich⁴, M. A. Griswold⁴, J. C. Carr⁵, and T. J. Carroll^{1,5}

¹Biomedical Engineering, Northwestern University, Chicago, IL, United States, ²Neurosurgery, Northwestern University, Chicago, IL, United States, ³Siemens Medical Solutions, Chicago, IL, United States, ⁴Radiology, University Hospitals of Cleveland, Cleveland, OH, United States, ⁵Radiology, Northwestern University, Chicago, IL, United States

Introduction:

Despite many improvements, there is a need for higher temporal resolution in time-resolved MRA. Current state-of-the-art techniques described either modify sampling patterns or modify the data collected over a relatively long period of time to achieve higher frame rates than the acquisition rate of a full data set. Even though some techniques achieve higher rate of image update, the temporal resolution ultimately depends on the “temporal footprint,” which is the span of the time window in which all the k -space points used to reconstruct a single image are acquired. Therefore, the only way to truly increase the temporal resolution is to decrease the acquisition time of a single frame.

A new 4D MRA technique called Contrast-enhanced Angiography with Multi-Echo and RAdial k -space (CAMERA) is introduced. With CAMERA, temporal footprint is reduced by a factor of 2 without parallel imaging or undersampling. Further acceleration is also possible by incorporating parallel imaging.

Methods:

In CAMERA, data is acquired in radial in-plane and Cartesian through-plane k -space, or “stack of stars.” Multiple-echoes are used in partition direction, in an interleaved manner to cover multiple partitions during each TR, similar to segmented echo-planar imaging. The multi-echo partitions are acquired in centric reordering scheme, which ensures that the central k -space region always contains the first readouts of the echo trains as well as the same readout polarity. Figure 1 illustrates the sampling schemes of CAMERA. With an echo train length of 4, approximately twofold acceleration is achieved. Sliding window reconstruction was applied to further increase the frame rate. GRAPPA was applied in through-plane direction for further acceleration.

Simulations, static phantoms, flow phantoms, and in vivo images were acquired using a Siemens 3T Trio to test the hypothesis that CAMERA results in better dynamic information while increasing SNR. SNR analysis was performed using bootstrap statistics. For static phantom study, vials filled with 1%, 2%, 4%, and 6.5% dilutions of Gd-DTPA were imaged with single-echo radial MRA and CAMERA, with and without GRAPPA. For flow phantom study, 2% Gd-DTPA solution was injected at 4ml/s into a silicone tube (3/8” inner diameter). For in vivo study, healthy volunteers and AVM patients were scanned with single-echo radial MRA and CAMERA, with and without GRAPPA.

Results:

Phantom studied showed that CAMERA images had approximately 30% higher SNR than single-echo radial MRA images, while CAMERA images also had narrower contrast bolus profiles, indicating more accurate dynamic information due to less temporal blur. In Vivo images showed better delineation of arteries and veins using CAMERA than conventional radial MRA due to higher SNR and better dynamic information (Figure 2).

Discussion and Conclusion:

The CAMERA technique achieves higher SNR in three ways. First, the acceleration in the acquisition increases SNR in MRA when the contrast agent signal is transient. Second, increase in TR from multi-echo imaging allows more time for re-growth of longitudinal magnetization. Lastly, the longer TR decreases the specific absorption rate (SAR), allowing the sequence to run at the optimized angle. For high field magnets (3T or higher), SAR is a limiting factor in image quality for fast sequences like spoiled gradient echo used in time-resolved MRA. In summary, CAMERA, a novel 4D MRA technique, achieves twofold acceleration without parallel imaging or undersampling while increasing SNR. CAMERA can be combined with parallel imaging for further acceleration.

References

1. Riederer et al. MRM 1988. 2. Luk Pat GT et al, MRM, 1997. 3. Beck G set al, MRM, 2001, 4. Cashen et al. MRM, 2007

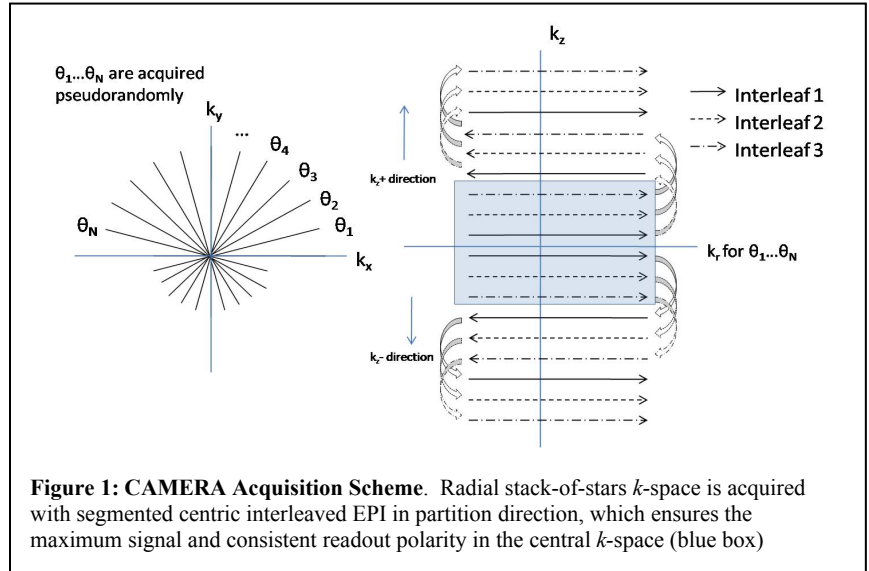


Figure 1: CAMERA Acquisition Scheme. Radial stack-of-stars k -space is acquired with segmented centric interleaved EPI in partition direction, which ensures the maximum signal and consistent readout polarity in the central k -space (blue box)

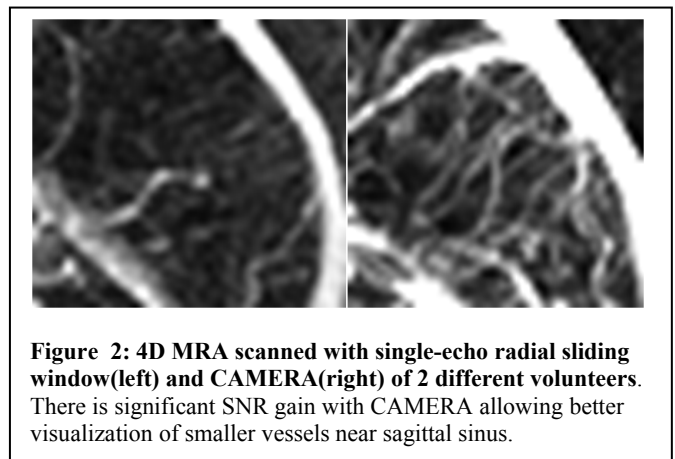


Figure 2: 4D MRA scanned with single-echo radial sliding window(left) and CAMERA(right) of 2 different volunteers. There is significant SNR gain with CAMERA allowing better visualization of smaller vessels near sagittal sinus.