

Hybrid calf magnetic resonance angiography using a time resolved technique

J. D. Collins¹, P. Hodnett¹, T. Scanlon¹, S. Zuehlsdorff², and J. Carr¹

¹Radiology, Northwestern University, Chicago, IL, United States, ²Siemens Healthcare, MR Research and Development

Background: Contrast-enhanced magnetic resonance angiography (CE-MRA) is an established reference standard for lower extremity angiography. Usually performed as a bolus-chase technique with multiple calf acquisitions, variations in arterial transit time and early arteriovenous shunting can compromise analysis of the calf vessels. Previous solutions included a hybrid technique with a dedicated calf station high-resolution acquisition prior to the bolus-chase examination of the pelvis and thighs. This addressed asymmetric transit times between the lower extremities; however, early arteriovenous shunting and the requisite high gadolinium dose remained problematic. To address these issues, we employed time-resolved imaging with stochastic trajectories (TWIST), which uses a spiral trajectory to undersample k-space, with parallel imaging to perform time-resolved imaging of the calf vessels.

Purpose: To report our experience in a patient cohort comparing low-dose TWIST-MRA calf angiography with bolus-chase CEMRA (BC-CEMRA).

Materials and Methods: A retrospective review of 22 consecutive patients with peripheral vascular disease who underwent CEMRA at 1.5 Tesla with TWIST and BC-CEMRA calf angiography. Two reviewers evaluated maximum intensity projection (MIP) images by consensus, assessing vascular segments for stenosis (No stenosis, <50%, 51-99%, or occluded), image quality (4 point Likert scale for venous signal contamination), and patency of the dorsalis pedis and medial plantar vessels. The calf vessels were divided into nine segments for stenosis grading and assessment of vascular patency. TWIST-MRA images alone were assessed for the presence of retrograde filling. TWIST-MRA parameters: 1.7 mm x 1.0 mm x 1.3 mm voxel, TR 2.4, TE 0.88, effective acquisition time 4.75 sec, parallel factor 2. BC-CEMRA parameters: 1.5 mm x 0.9 mm x 1.3 mm voxel, TR 2.64, TE 0.94, 11 sec acquisition time, parallel factor 2.

Results: With consensus interpretation of the BC-CEMRA MIP images as the reference standard, accuracy for identifying a stenosis > 50% was 96%, with a sensitivity of 94% and a specificity of 98%. The negative and positive predictive values were 99% and 92% respectively. Agreement between TWIST-MRA and CE-MRA was good at 82.5% and exceeded the expected agreement of 34.6% with a kappa of 0.73. 5 vascular segments thought to be occluded at CE-MRA were seen to be patent but diseased at TWIST-MRA; 4 vascular segments thought to be diseased at CE-MRA were seen to be occluded with collateral vessels at TWIST-MRA. TWIST image quality was graded superior to BC-CEMRA with average Likert scores of 3.8 and 3.3 respectively (p<0.05); two BC-CEMRA datasets were graded as non-diagnostic. 64% of the medial plantar and dorsalis pedis vessels were patent at BC-CEMRA compared to 70% at TWIST-MRA; 5 vessels in 4 patients thought to be occluded at CE-MRA were patent on TWIST-MRA. Retrograde arterial filling was identified in 5 patients (23%). Gadolinium dose for the TWIST-MRA averaged 0.04 mmol/kg.

Conclusions: TWIST-MRA consistently obtained high-quality calf images, free of venous contamination compromising interpretation in all patients. This low dose technique enabled differentiation of collateral vessels and veins and demonstrated retrograde arterial filling. Despite a lower spatial resolution, the sensitivity for detecting significant stenosis was excellent with good agreement with the reference standard BC-CEMRA. TWIST-MRA is a useful addition to standard BC-CEMRA of the lower extremities. Further work is ongoing to evaluate the therapeutic impact of TWIST-MRA in choosing bypass targets and lesions for endovascular therapy.

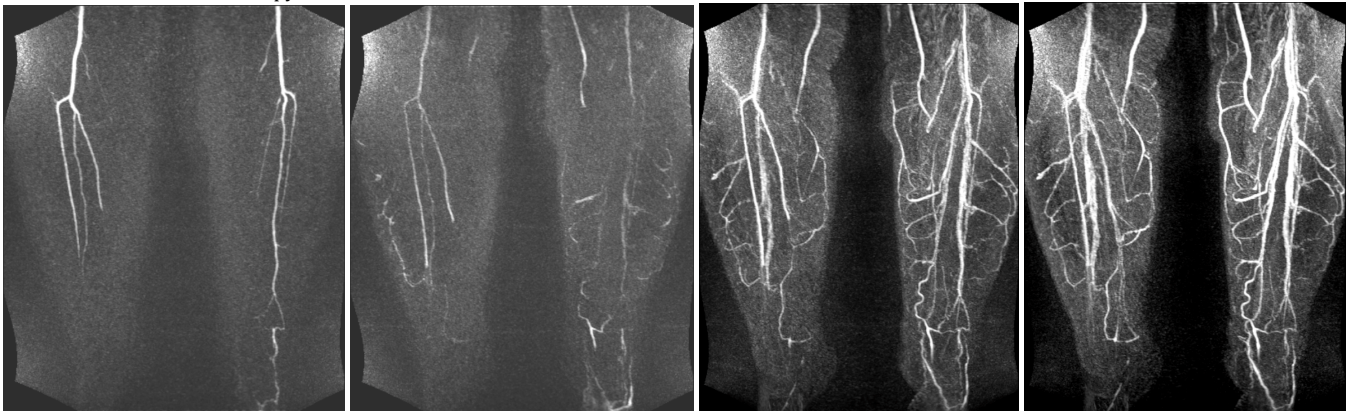

Figure 1: Calf images from a 58 year-old female with arterial thromboembolism to the right lower extremity. TWIST acquisition in (A) early and (B) late arterial phases. BC-CEMRA of the calves demonstrates venous contamination on both the (C) 1st and (D) 2nd acquisitions.

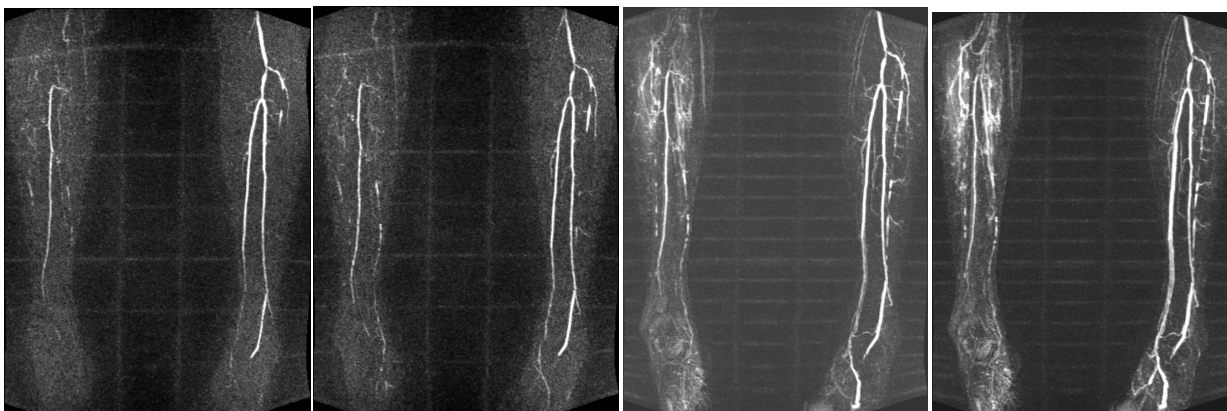


Figure 2: Calf images from a 65 year old male with peripheral occlusive vascular disease and asymmetric lower extremity transit times. From left to right: early arterial TWIST, late arterial TWIST, BC-CEMRA 1st measurement, and BC-CEMRA 2nd measurement. Clear separation of arterial and venous phases is achieved at TWIST.