

## Diagnostic Performance of Gadobenate Dimeglumine and Gadopentetate Dimeglumine for Peripheral MRA: Multicenter Comparison with DSA

T. Leiner<sup>1</sup>, S. C. Gerretsen<sup>2</sup>, T. le Maire<sup>2</sup>, S. Miller<sup>3</sup>, S. Thurnher<sup>4</sup>, C. U. Herborn<sup>5</sup>, H. J. Michaely<sup>6</sup>, H. Kramer<sup>7</sup>, A. Vanzulli<sup>8</sup>, J. Vymazal<sup>9</sup>, and M. Wasser<sup>10</sup>

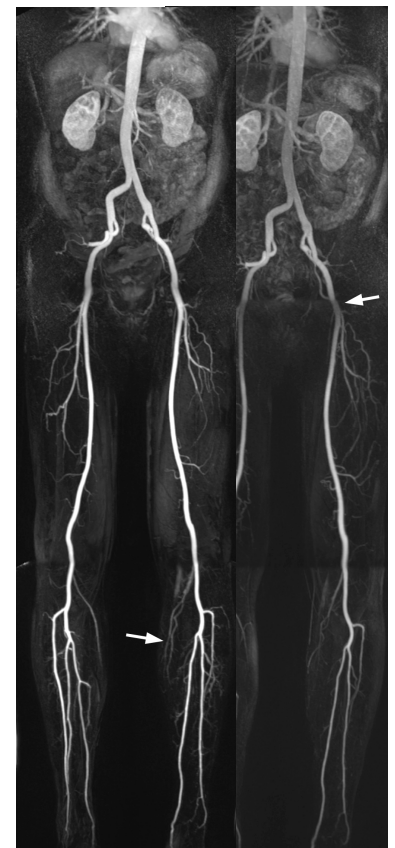
<sup>1</sup>Radiology, Maastricht University Hospital, Maastricht, Netherlands, <sup>2</sup>Radiology, Catharina Hospital, Eindhoven, Netherlands, <sup>3</sup>Radiology, Eberhard-Karls University, Tübingen, Germany, <sup>4</sup>Radiology, Hospital of St. John of God, Vienna, Austria, <sup>5</sup>Radiology, University Medical Center Hamburg-Eppendorf, Hamburg, Germany, <sup>6</sup>Institute of Clinical Radiology, University Hospital Mannheim, Mannheim, Germany, <sup>7</sup>Radiology, Ludwig Maximilians University, Munich, Germany, <sup>8</sup>Hospital Niguarda Ca' Granda, Milan, Italy, <sup>9</sup>Radiology, Na Homolce Hospital, Prague, Czech Republic, <sup>10</sup>Radiology, Leiden University Medical Center, Leiden, Netherlands

**Purpose:** CE-MRA represents a noninvasive alternative to DSA for evaluation of the peripheral vessels. We prospectively compared the diagnostic performance of gadobenate dimeglumine (Gd-BOPTA) and gadopentetate dimeglumine (Gd-DTPA) for contrast-enhanced MR angiography (CE-MRA) in patients with suspected peripheral arterial vascular disease (PAOD) using digital subtraction angiography (DSA) as the reference standard.

**Materials and Methods:** 96 adult patients with suspected moderate-to-severe PAOD were enrolled at 7 investigational sites between November 2006 and January 2008 and underwent 2 identical 1.5 T, 3-station, CE-MRA examinations from the aortic bifurcation to the lower leg. For the 2 exams, patients received equal 0.1 mmol/kg bw doses of gadobenate dimeglumine and gadopentetate dimeglumine in random order. Diagnostic performance in terms of sensitivity, specificity, accuracy, positive predictive value (PPV), and negative predictive value (NPV), was determined in the subset of patients (n=31) that also underwent DSA. The presence and extent of steno-occlusive disease on DSA images was determined on a segmental basis using a 4-point scale: 1=stenosis <25%; 2=stenosis >25%–<51% 3=stenosis >51%–99%; and 4=occlusion). Statistical analyses were performed using the Wilcoxon Signed Rank, McNemar, and Wald tests.

**Results:** Overall, 397 segments from 96 patients were evaluated by DSA, and 270 (68.0%) segments were determined to have stenoses of <51% while 127 (32.0%) segments were considered to harbor significant ( $\geq 51\%$ ) stenoses. Each of the 3 blinded readers reported significantly ( $P \leq 0.0017$ ) better diagnostic performance with gadobenate dimeglumine than with gadopentetate dimeglumine, with increases of 11.0%–18.1% in sensitivity, 4.4%–9.3% in specificity, and 7.8%–10.1% in overall accuracy across the 3 readers. Each reader also reported significantly ( $P \leq 0.0028$ ) higher predictive values with gadobenate dimeglumine, with differences ranging from 12.7%–19.3% for PPV and 5.5%–7.9% for NPV across all 3 readers.

**Conclusions:** CE-MRA of the peripheral vasculature is a noninvasive alternative to DSA. Use of 0.1 mmol/kg gadobenate dimeglumine provides significantly better diagnostic performance compared to an equivalent dose of gadopentetate dimeglumine in terms of sensitivity, specificity, accuracy, PPV, and NPV.



Gadobenate Dimeglumine      Gadopentetate dimeglumine