

Aortic pulse pressure evaluation using Fourier velocity encoded MR M-mode

V. Taviani¹, S. S. Hickson², C. J. Hardy³, A. J. Patterson¹, V. E. Young¹, M. Butlin⁴, C. M. McEnery², I. B. Wilkinson², J. H. Gillard¹, and M. J. Graves¹

¹Department of Radiology, University of Cambridge, Addenbrooke's Hospital, Cambridge, United Kingdom, ²Clinical Pharmacology Unit, University of Cambridge, Addenbrooke's Hospital, Cambridge, United Kingdom, ³GE Global Research, Niskayuna, New York, United States, ⁴The Australian School of Advanced Medicine, Macquarie University, Sydney, Australia

Introduction

Central pulse pressure (PP) is closely related to aortic stiffness and represents a major determinant of ventricular afterload [1]. Brachial PP is often used as a surrogate of central PP. However, due to amplification of the pressure pulse away from the heart [2], peripheral measurements can substantially overestimate central values [3] and intravascular procedures are needed for reliable assessment of central pressures.

Previous MR studies used multi-slice 2D phase contrast with through-plane velocity encoding and a simplified form of the cross-section-averaged flow continuity and momentum equations to estimate PP in the aorta [4, 5]. Major limitations of this method were the long acquisition times, low temporal resolution and the inability to perform spatially localized measurements. Fourier velocity encoded (FVE) M-mode can provide velocity spectra versus time and position along a relatively straight vascular segment with high temporal (4ms) and spatial (0.9mm) resolution in about 2min [6]. In this work, a methodology for PP estimation in the aorta, based on FVE M-mode and a hemodynamic model similar to the one in [4], is presented and validated against applanation tonometry (AT) performed in a cohort of 18 healthy volunteers and intravascular pressure measurements (IVPM) obtained in 4 patients referred for diagnostic catheterization.

Methods

Eighteen healthy volunteers (age range: 25-57 years, mean age: 38.8 years) and 4 patients undergoing diagnostic cardiac angiography (age range: 58-78 years, mean age: 68.8 years) took part in the study after giving written informed consent. Imaging was performed on a 1.5T whole-body imaging system (Signa HDx, GE Healthcare, Waukesha, WI) using an 8-channel abdo-torso phased-array surface coil.

After localization of the descending aorta (Figure 1a), an 8-turn spiral excitation pulse was used to excite a cylinder (2cm diameter) of spins within the vessel [6]. A bipolar gradient incremented through 32 velocity-encoding steps on each new ECG-trigger, followed by a readout gradient along the axis of the cylinder, produced velocity distributions along the vessel as a function of time (Figure 1b). Four interleaves of the data produced a total of 128 cardiac phases, covering the first 450ms of the cardiac cycle. A velocity range of 150cm/s and a 24cm readout field-of-view (matrix size = 256x32) were used.

The obtained time series of FVE M-mode images were reformatted to yield Doppler-like time-velocity traces along the vessel (Figure 1c) [7]. Integration of the velocity spectrum at each position and cardiac phase produced the average velocity surface shown in Figure 1d. The average velocity profile obtained from FVE M-mode and 2D cine phase contrast (CPC) with through-plane velocity encoding at a given spatial location along the vessel are compared in Figure 1e.

As already demonstrated in [4], $\partial p / \partial t = \rho \bar{w} \partial \bar{w} / \partial t - \rho \cdot (PWV)^2 \partial \bar{w} / \partial z$ (Eq. 1), where ρ is the blood density ($\rho=1060\text{kg/m}^3$), PWV is the pulse wave velocity and p and \bar{w} are the average cross-sectional pressure and velocity (axial component, vessel axis aligned with z), respectively. PWV was obtained by best fit of the foot of the wave as a function of position along the vessel, with the foot of the wave defined as the intersection between the early systolic upslope and the zero velocity line. Numerical evaluation of Eq. 1 over 6cm long segments along the excited cylinder (Figure 1) yielded the temporal pressure gradient as a function of time and position and, by integration, the local PP. For each subject, a series of measurements were performed at different locations along the descending aorta and the mean PP (\pm std) was compared against AT, as performed in the 18 volunteers and IVPM, previously obtained for the 4 patients. AT (SphygmoCor, AtCor Medical, Sydney, Australia) of the radial artery with brachial mean and diastolic pressure calibration provided the central pressure waveform by means of an extensively validated generalized transfer function [8]. IVPM were obtained by means of a continuous 5F catheter pullback, from 1cm distal to the aortic valve down to the femoral artery, through which the catheter was inserted.

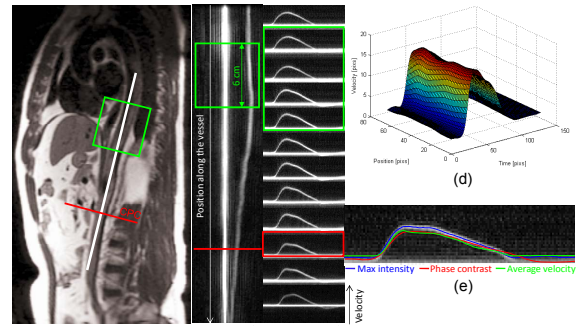


Figure 1

Results

The root mean square (RMS) error between MR- and AT-derived pressure waveforms, over the first 400ms of the cardiac cycle, was $10.3 \pm 5.9\%$, similar to the $8.2 \pm 3.4\%$ RMS reported by Urchuk *et al.* in 3 pigs [5]. With respect to IVPM, the RMS error ranged from 8.8% to 25%, with the largest error found in the two oldest subjects (highest PP and PWV). Figure 2 shows the MR- and AT-derived pressure waveforms for a healthy volunteer aged 57 (measurement site: 6cm above diaphragm, RMS=2.2mmHg). MR-derived vs. AT-derived (black circles) and vs. IVPM-derived (red squares) PPs are compared in Figure 3 and in the Bland-Altman plot in Figure 4. MR-derived PPs appear to be slightly overestimated with respect to AT (bias=1.25; 95% limits of agreement (LOA) = [-5.7 to 8.2, range 13.9]), probably due to the fact that while AT estimates the pressure pulse in proximity to the aortic valve, the MR measurements were made more distally, in the descending aorta.

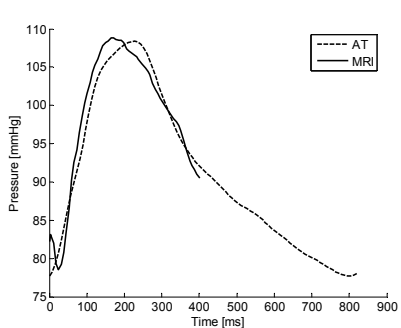


Figure 2

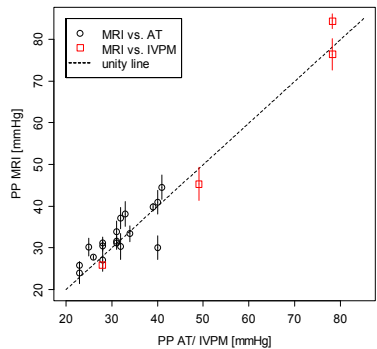


Figure 3

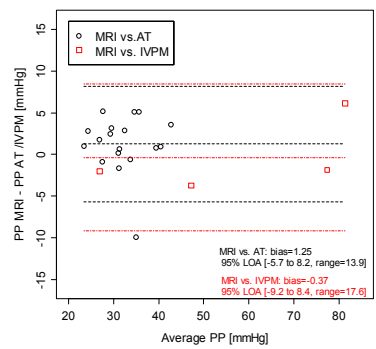


Figure 4

Conclusion

We have developed and validated a methodology based on FVE M-mode and cross-section-averaged flow equations for central PP evaluation. Good agreement was found with AT and IVPM, although larger RMS errors were found in older subjects.

References

- [1] Safar ME, et al. Adv. Cardiol. 2007; 44:1-18.
- [2] O'Rourke MF, et al. Circ. Res. 1968; 23:567-79.
- [3] Laurent S, et al. Eur. Heart J. 2006; 27: 2588-605.
- [4] Urchuk SN, et al. JMRI 1995; 5: 621-7.
- [5] Urchuk SN, et al. MRM 1997; 38:215-23.
- [6] Hardy CJ, et al. MRM 1996; 35(6):814-9.
- [7] Hardy CJ, et al. ISMRM08.
- [8] Chen CH, Circulation 1997; 95:1827-36.