

Navigator gated and cardiac triggered echo-planar spectroscopic imaging of the heart

K. Weiss¹, N. Martini², P. Boesiger¹, and S. Kozerke¹

¹Institute for Biomedical Engineering, University and ETH Zurich, Zurich, Switzerland, ²Interdepartmental Research Center "E. Piaggio", University of Pisa, Pisa, Italy

Introduction

Single-voxel proton magnetic resonance spectroscopy has been shown to be a promising tool for assessing creatine [1] and myocardial triglycerides in humans [2]. A focus of interest is the correlation between triglyceride content in the myocardium and cardiac dysfunction [3]. While spectral information from a single volume is sufficient when alterations with global effects on the heart are studied, a demand for higher and flexible spatial resolution exists when probing local changes. To this end, implementation of fast spectroscopic imaging of the heart is desired. In order to compensate for cardiac and respiratory motion, navigator-based dual triggering has been proposed [4] which has been found to be a prerequisite for reproducible proton spectroscopy of the heart [5].

The objective of the current work was to implement and optimize navigator gated and cardiac triggered Echo-Planar Spectroscopic Imaging (EPSI) for assessment of triglyceride and creatine content in the myocardium in vivo.

Methods

Navigator gated EPSI (Figure 1) was implemented on a 1.5T Philips Achieva system (Philips Healthcare, Best, The Netherlands) with following parameters: field-of-view: 300x246 mm², spatial resolution: 3x3 mm², slice thickness: 15 mm, spectral bandwidth: 1390 Hz, spectral resolution: 5.4 Hz, 8 signal averages, Ernst angle: 70 deg (fat), cardiac trigger delay: 300 ms, 5-element cardiac coil array for signal reception. Water-suppressed and unsuppressed EPSI data were acquired in healthy volunteers during free breathing in an average scan time of 2:30 min per average depending on heart rate and respiratory navigator efficiency. For image reconstruction a gridding approach was employed to account for gradient slope sampling used. Prior to spectral processing, signals from the individual receive coils were combined using coil sensitivities derived from the first points in the FIDs of each coil. Spectral N/2 ghost resulting from delays between even and odd readout gradients were corrected by maximizing the water signal in the water unsuppressed reference scan [6]. To minimize the side lobes of the spatial point spread function the k-space data were filtered using a Hamming window. A field-map was calculated from the position of the water peak in the unsuppressed EPSI scan (Figure 2a) and frequency shifts due to field inhomogeneities were corrected. The water-suppressed EPSI scans were corrected using the correction parameters obtained from the reference scan acquired without water suppression. Data from different averages were phased individually to ensure phase coherent signal addition.

Results

Field map values across the heart varied between 30Hz to 40Hz after shimming (Figure 2a). Accordingly sufficient water suppression was seen (Figure 2b). Images from EPSI scans acquired without water suppression showed no visible motion artifacts. However, spectra of individual averages did reveal phase differences due to residual bulk motion. Figure 3a-b shows a balanced SSFP short-axis view of the heart along with the image of the water resonance from the EPSI reference scan. In Figure 3c-d spectra from a single voxel in the septal wall as indicated in Figure 3b are displayed. The spectrum generated from 8 signal averages shows both the creatine and the triglyceride resonances.

Discussion

It has been demonstrated that navigator-gated and cardiac triggered EPSI can be used to assess myocardial triglyceride and creatine resonances during free-breathing acquisitions. Residual motion, however, demands individual phasing of signal averages and future work is warranted to assess the robustness of the approach in a larger study population.

- [1] Bottomley et al. Lancet 351 (1998)
- [2] Szczepaniak et al. Magn. Reson. Med. 49 (2003)
- [3] Rijzewijk et al. JACC 52, 22 (2008)
- [4] Schär et al. Magn. Reson. Med. 51 (2004)
- [5] v. d. Meer et al. Radiology 245 (2007)
- [6] Du et al. Magn. Reson. Med. 49 (2003)

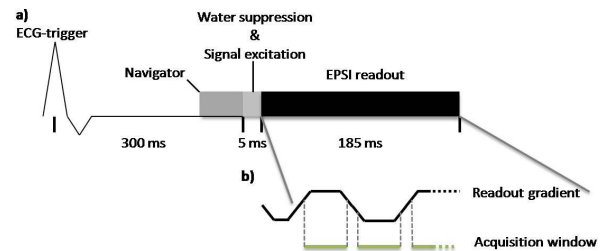


Figure 1: Schematic of the navigator gated EPSI sequence a) using echo planar readouts with fractional slope sampling b).

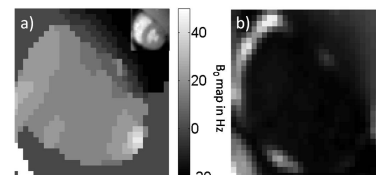


Figure 2: Cardiac field map computed from an EPSI scan acquired without water suppression a). The sum over all resonances in the water suppressed EPSI scan shows only signal from the epicardial fat around the heart demonstrating sufficient water suppression.

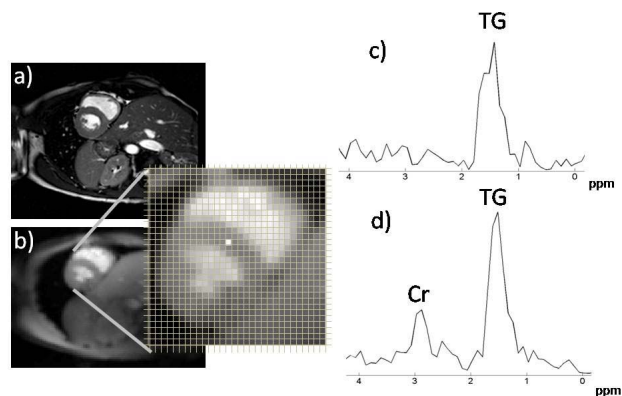


Fig. 3: Short-axis view a), image of the water resonance of the unsuppressed EPSI reference b), single average proton spectrum with the triglyceride (TG) resonance from the septal wall (marked voxel in b) c) and corresponding spectrum from 8 signal averages showing creatine (Cr) at 3.03 ppm d).