

Myocardial extracellular volume imaging - phantom validation and patient feasibility for quantitative pixel mapping of the fractional distribution volume of extracellular contrast agents by MRI

M. Ugander¹, A. J. Oki¹, P. Kellman¹, A. Greiser², A. H. Aletras¹, and A. E. Arai¹

¹National Heart, Lung and Blood Institute, National Institutes of Health, Bethesda, MD, United States, ²Siemens AG Healthcare Sector, Erlangen, Germany

Background: Recent developments in rapid and accurate T1 mapping sequences (Messroghli, et al, JMRI, 2007) have made it practical to image the extracellular volume (ECV) fraction, which has been previously validated in animal studies (Arheden, et al, Radiology, 1999). However, generating accurate quantitative pixel map images of the ECV in vivo requires obtaining a blood sample to measure the hematocrit, and accurate quantification of T1 in blood and myocardium before and after intravenous contrast administration. **Objective:** Therefore, the aims of the study were to perform comprehensive phantom validation and calibration of T1 mapping in blood and myocardium, and to illustrate the feasibility of quantitative ECV imaging in patients.

Methods: Phantom T1 quantification was performed using a Modified Look-Locker Inversion-recovery (MOLLI) sequence (Messroghli, et al, JMRI, 2007) at 1.5T (Siemens) and results were compared to an inversion-recovery spin-echo (IR-SE) sequence which served as the reference standard. Phantom T2 was quantified using a saturation-recovery spin-echo sequence. Phantoms comprised of agarose gel doped with cupric sulfate ranged in T1 from 301-1625ms and T2 from 69-250ms. MOLLI imaging was performed using simulated heart rates ranging from 40-120 beats per minute (bpm). In order to study the effect of blood movement upon T1, dogs were imaged with MOLLI in an imaging plane encompassing the left ventricular blood pool and a syringe of freshly withdrawn arterial blood placed adjacent to the body. Fifteen consecutive patients underwent venous blood sampling for hematocrit measurement and were imaged with MOLLI before and after contrast administration, and ECV images were generated. Also, ECV values using T1 fitting based on 11 MOLLI images were compared to using only 8 images, by exclusion of the three images acquired during the second inversion pulse.

Results: In phantoms, T1 estimates by MOLLI were linearly related to T1 by IR-SE up to ~1000ms, but tended to underestimate longer T1. The underestimation was more pronounced for higher heart rates (See figure). Calibration compared to IR-SE yielded a corrected T1 by MOLLI, using 11 images, which differed by 1.4+/-3.9% compared to IR-SE over the studied ranges of T1, T2 and heart rate. Similarly, T1 from MOLLI using only 8 images in phantoms differed by 2.9+/-3.6% compared to IR-SE. In 6 dogs, non-moving pre-contrast arterial blood in a syringe differed in T1 from moving blood in the left ventricle by 0.3+/-2.1% (1599 +/-141ms vs. 1603+/-109ms). In Bland-Altman analysis, the mean difference in patients for ECV derived from uncorrected MOLLI vs. corrected MOLLI was 0.0+/-0.3 percentage points. ECV values for normal myocardium using corrected MOLLI T1 values based on fitting of 8 MOLLI images differed from fitting of 11 MOLLI images by 0.8+/-0.7 percentage points.

Conclusions: It is feasible to generate quantitative ECV images of the myocardium in patients. These images can be acquired using only 8 MOLLI images acquired in a shorter breath hold. Accurate T1 quantification in the pre-contrast myocardium is dependent on heart rate, and thus calibration correction may be of value for quantitative comparisons between subjects. ECV calculations are less dependent on calibrated T1 values, since errors in T1 are systematic and cancel out in the calculation of ECV.

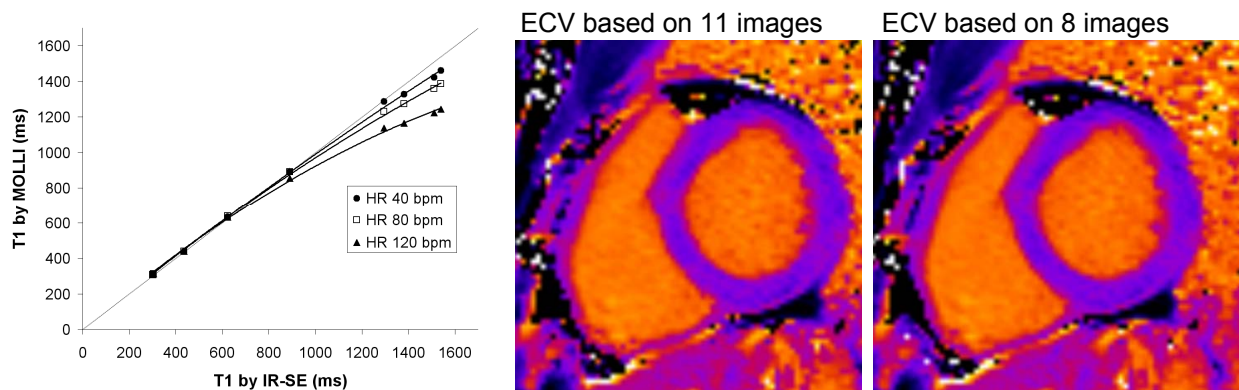


Figure. LEFT: The MOLLI sequence showed a progressively larger underestimation of T1 values compared to IR-SE in phantoms as heart rate (HR) and T1 increased. Dotted line is the line of identity. MIDDLE and RIGHT: Quantitative parametric maps of the extracellular volume (ECV) fraction in a midventricular short-axis plane in a patient with an ECV in normal myocardium of 23+/-2%. ECV values did not differ when using 11 or 8 MOLLI images as the basis for pre- and post-contrast T1 calculations.