

fcMRI plasticity following rat median nerve injury and repair at 9.4T

R. Li¹, P. Hettinger², Y. Cho¹, C. P. Pawela¹, M. Parkins², S. Jones², J-G. Yan², A. Jesmanowicz¹, A. Hudetz³, H. Matloub², and J. Hyde¹

¹Biophysics, Medical College of Wisconsin, Milwaukee, WI, United States, ²Plastic Surgery, Medical College of Wisconsin, Milwaukee, WI, United States,

³Anesthesiology, Medical College of Wisconsin, Milwaukee, WI, United States

Introduction

In our previous studies, we demonstrated cortical plasticity and recovery of the sensory-motor cortex of the rat following peripheral nerve injury and repair (1, 2) using fMRI and direct nerve stimulation. Monitoring the plasticity of the cortex is problematic due to the loss of input following nerve injury and the slow regenerative rate of nerve fibers. No functional data are obtained by stimulating the target nerve. It is also difficult clinically to monitor cortical plasticity because after nerve injury and repair the affected nerve needs to be immobilized and sensory paralysis exists for a long time even though neurotomy is properly done. In this study, we show that by using resting-state MRI connectivity (R-fMRI), we can distinguish nerve injury, nerve repair, and sham control in a rat model. This study provides a potential method to monitor cortical plasticity following nerve injury and repair of a peripheral nerve. In addition, it is expected to be useful in other animal models of disease and intervention.

Method

Animal preparation: Thirty-six Sprague-Dawley rats were used in this study, divided into two groups: acute and sub-acute. In each group, rats were further divided into three sub-groups: nerve injury, nerve injury and repair, and sham control. For rats in the nerve injury sub-groups, the right median nerve was exposed and transected 1 cm above the elbow. For rats in the nerve injury and repair sub-groups, the same nerve injury was made, and the transected nerve was repaired under a microscope immediately following injury. For rats in the sham control sub-groups, the right median nerve was exposed without additional manipulation. All rats in acute groups were scanned as soon as possible after surgery. Rats in sub-acute groups were allowed to recover from anesthesia and scanned two weeks later. During scans, a copper electrode was attached on the healthy forepaw on the left side to carry out stimulation. During scans, rats were ventilated to maintain a stable physiological status. The right femoral vein was used for drug delivery. Physiological parameters were closely monitored during surgery and scans. All rats were sacrificed after scans. **Anesthesia:** Isoflurane (1.4%) was administered during the surgical portion of the procedure. Once the rat was transferred to the scanner, the isoflurane was turned off. A continuous infusion of pancuronium bromide (2 mg/kg/hr) and Domitor (0.1 mg/kg/hr) was used during the fMRI acquisition. **Stimulation protocol:** For the functional scan of healthy left forepaw representations, electrical stimulation of 10 Hz, 2 mA with a constant duration of 3ms was used. The stimulation sequence began with an OFF period of 40 s followed by three repetitions of ON for 20 s and OFF for 40 s (total scan time = 3 min 40 s). There was a four-minute resting time between stimulations. **fMRI parameters:** A 9.4 T small-animal scanner (AVANCE; Bruker, Billerica, MA) was used. First, a RARE anatomy image was acquired with 10 continuous slices with 1 mm slice thickness. The third slice was located over the anterior commissure. After that, a continuous resting-state scan was conducted without task stimulation for 3 min and 40 s followed by BOLD contrast fMRI acquisition while stimulating the healthy forepaw on the left side. Gradient recalled echo planar scans were used in both runs (single-shot EPI, TE = 18.76 ms, TR = 2 sec, FOV = 3.5 cm, 10 contiguous interleaved 1 mm slices, matrix size 96 × 96). **Data analysis:** A seed-voxel was chosen from the healthy forepaw activation scan. We used cross-correlation analysis between the average time course of six reference voxels at the center of the highest cortical activation chosen from the functional anatomy, and that time course was correlated with every other voxel time course in that slice. A low-pass filter with a cutoff at 0.08 Hz was applied to all voxel time courses. All data were registered to a standard anatomical template, and then the group T test was carried out. All voxels that passed a correlation coefficient threshold of 0.35 were considered significant (3).

Results

Figure 1 displays the resting-state connectivity map that uses a reference time course, obtained as described above, from healthy left forepaw stimulation. Figure 1a shows, in the acute stage, that there is a significant signal drop whether or not neurotomy was done. Bilateral activation was greatly suppressed. Figure 1b shows results two weeks after the initial injury. Bilateral activation can be seen in all three groups. The sham control group remains almost the same compared with the acute-stage data. Bilateral activation in the nerve-cut group is suppressed; although in comparison with the acute stage, it is better. The functional connectivity of the nerve-repair group is almost the same as that of the sham control group. Bilateral signals can be seen from all rats.

Conclusion and Discussion

In this study, we investigated fcMRI plasticity in the cortical sensory-motor area caused by different peripheral nerve manipulations. Nerve repair restored the connectivity map from the highly suppressed unilateral presentation back to a normal map. The map of the transected nerve group remained suppressed. There is a minor difference between the two sham groups. It could be the result of scar tissue that compressed the nerve trunk in the two-week group. It is clear that whether the nerve was repaired after injury or not, in the acute stage, the resting-state maps remained the same, and this would last for several days. The difference between nerve-cut and nerve-repair increases as time passes. The rat forepaw is innervated by both the median and ulnar nerves. In this study, the transected median nerve only leads to a partial sensory loss of forepaw innervation, which leads to a partial breakdown of the cortical sensory network. We expect the decline of functional connectivity in the cut group to be more prominent if both median and ulnar nerves are transected. We also believe that the plasticity difference between the nerve-cut and nerve-repair groups could become more apparent at a longer recovery time.

References

1. Cho YR, Hyde JS et al. *Magn Reson Med*. 2007 Nov; 58(5):901-9.
2. Li R, Hyde JS et al. *Proc. Intl. Soc. Mag. Reson. Med*. 17(2009) 125.
3. Pawela CP et al. *Magn Reson Med*. 2008 May; 59(5):1021-9.

Acknowledgements

This work was supported by grant EB000215 from the National Institutes of Health.

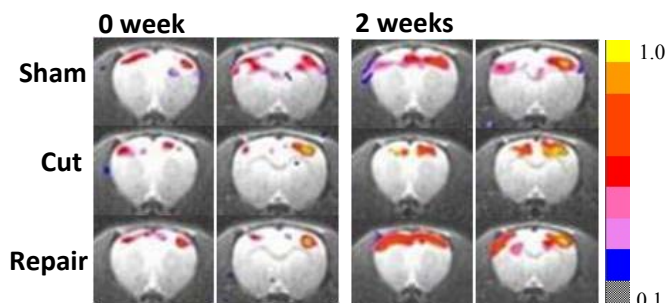


Figure 1. Functional connectivity maps of acute stage (a) and sub-acute stage (b). Note that after neurotomy, in the sub-acute stage, the fcMRI map was restored and became similar to the sham group, while the cut group remained suppressed ($P < 0.001$).