

# Myocardial T1-Mapping in chronic myocardial infarction: Results of unenhanced and contrast enhanced MR imaging using Gadobutrol

K. U. Bauner<sup>1</sup>, A. Biffar<sup>2</sup>, D. Theisen<sup>1</sup>, T. Sandner<sup>1</sup>, A. Greiser<sup>3</sup>, M. F. Reiser<sup>1</sup>, and B. Wintersperger<sup>1</sup>

<sup>1</sup>Department of Clinical Radiology, LMU Munich - Campus Grosshadern, Munich, Germany, <sup>2</sup>Josef Lissner Laboratory for Biomedical Imaging, LMU Munich - Campus Grosshadern, Munich, <sup>3</sup>Siemens medical solutions

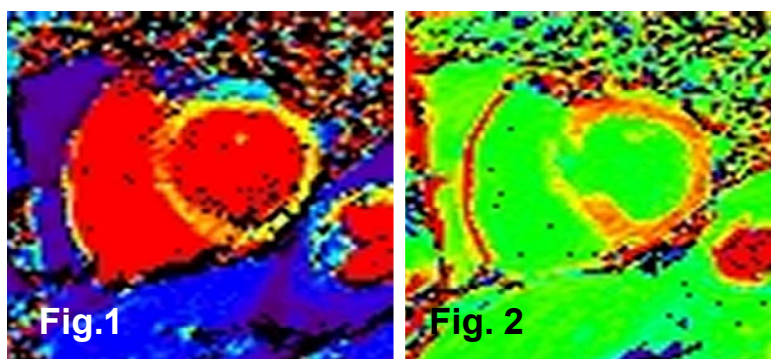
## Purpose:

At a given field strength tissues present with specific  $T_1$ -values. Reference values for normal unenhanced myocardium have been established. We hypothesize, that infarcted myocardial tissue can be delineated from normal myocardium by means of  $T_1$ -maps in unenhanced and contrast-enhanced scans.

## Materials and Methods:

18 patients with chronic myocardial infarction were examined at 1.5T (Magnetom Avanto, Siemens Healthcare). A modified Look-Locker inversion recovery (MOLLI) sequence (TR/TE 200.7/1.03msec; TI 100-4000msec; flip 35°) was performed pre- and 10min post-contrast (0.15mmol/kg Gadobutrol, Bayer Schering Pharma) at an apical, midmyocardial and basal short axis position. For calculation of  $T_1$ -values signal intensities of myocardial and infarcted tissue were measured at 11 points of time<sup>1</sup> with two blocks of 3 and a third block 5 consecutive image acquisitions. Within each block TI increased by steps of 80 msec. 15 minutes after contrast medium application a single slice IR GRE was employed for imaging of delayed enhancement.

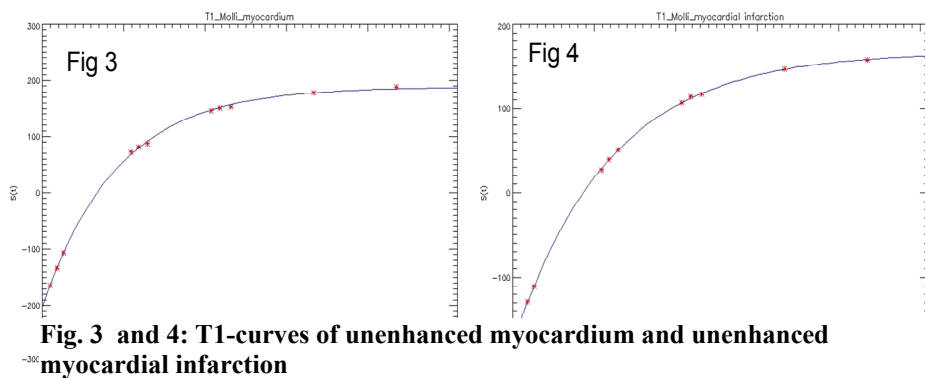
Data were post-processed with an in-house built software (PMI 0.4).  $T_1$  maps were created on the basis of unenhanced (fig. 1) and enhanced (fig. 2) data. Areas of normal and infarcted myocardial tissue were identified on delayed enhancement images and the regions of interest were copied to the unenhanced and enhanced MOLLI images. The analyses of  $T_1$ -values were performed for normal myocardium (MYO), infarcted myocardium (CMI) and the left ventricular cavity (LVC). In addition  $T_1$ -ratios of MYO/LVC and CMI/LVC were calculated. Student's t-test was used for statistical analysis of acquired and calculated data.



**Fig. 1 and 2:** 53 y/o male patient with myocardial infarction (septum). Colour coded  $T_1$  maps before (fig. 1) and after administration of contrast material (fig. 2).

## Results:

The comparison of  $T_1$ -values of MYO (fig. 3) and CMI (fig. 4) revealed significant differences in pre-contrast scans ( $1024 \pm 38$  vs.  $1200 \pm 57$  msec;  $p < 0.001$ ), as well as CMI  $T_1$ -values in comparison to LVC ( $1200 \pm 57$  vs.  $1502 \pm 70$  msec;  $p < 0.001$ ). The calculated ratios of MYO/LVC and CMI/LVC were also significantly different ( $0.68 \pm 0.04$  vs.  $0.79 \pm 0.05$ ;  $p < 0.001$ ) in pre-contrast scans. In post-contrast evaluations differences of  $T_1$ -values in MYO and CMI



**Fig. 3 and 4:**  $T_1$ -curves of unenhanced myocardium and unenhanced myocardial infarction

were equally high ( $365 \pm 46$  vs.  $231 \pm 52$  msec;  $p < 0.001$ ) resulting in significantly different  $T_1$ -ratios of MYO/LVC ( $1.5 \pm 0.19$ ) and CMI/LVC ( $1.0 \pm 0.11$ ;  $p < 0.001$ ).

## Conclusions:

MR-measurements of  $T_1$ -values with the LVC as reference allow for differentiation of infarcted areas from normal myocardium.

Further studies are warranted for a normalization of values in order to reduce the dependency on contrast timing, dose and agent.

<sup>1</sup> Daniel R. Messroghli et al. JMRI 2007, Optimization and Validation of a Fully-Integrated Pulse Sequence for Modified Look-Locker Inversion-Recovery (MOLLI)  $T_1$  Mapping of the Heart, 26:1081–1086,