

Histology assisted validation of automatic detection of soft plaque in vessel wall images by using optimal number of MR sequences

R. van 't Klooster¹, A. J. Patterson², V. E. Young², J. H. Gillard², J. H. Reiber¹, and R. J. van der Geest¹

¹Division of Image Processing, Department of Radiology, Leiden University Medical Center, Leiden, Netherlands, ²University Department of Radiology, Cambridge University Hospitals NHS Foundation Trust, Cambridge, United Kingdom

Introduction: Carotid atherosclerosis is characterized by the accumulation of lipid, protein, and cholesterol esters in the vessel wall causing at an early stage remodeling of the vessel wall, and at a later stage luminal narrowing and formation of plaques in the vessel wall. Unstable plaques, plaques containing a large lipid pool or intraplaque hemorrhage, are of special interest. There is growing evidence that these plaques, also called soft plaques, are indicators of future vascular events such as plaque rupture causing stroke. MRI can non-invasively visualize both stable and unstable plaques enabling identification of subjects at risk. Moreover, MRI protocols can be designed with optimized sensitivity to specific physical characteristics of the plaque components. Usage of such a multi-sequence vessel wall imaging protocol enables the identification of plaque components in the carotid vessel wall. However, the manual segmentation of the plaque is a labor-intensive and observer dependent task. Moreover, the usage of an extensive multi-sequence protocol is time consuming, both occupying the scanner and resulting in discomfort for the subject.

Therefore, the purpose of the study was to utilize a computer-aided diagnosis system for automatic detection of atherosclerotic plaques in carotid arteries to assess the relative value of the individual sequences used in an extensive vessel wall MR imaging protocol. By evaluating the performance of the system we are able to evaluate what the optimal sequence set is in order to reliably detect unstable plaques.

Methods: Sixteen subjects (12 male, age range 50-89), scheduled for carotid endarterectomy, were pre-operative scanned using a vessel wall imaging protocol. MR imaging was performed on a 1.5T scanner (Signa HDx, GE Healthcare, Waukesha, WI) using a dedicated 4-channel carotid coil array (PACC, Machnet, Eelde, The Netherlands). A 2-D time-of-flight (TOF) sequence was performed to identify the diseased arterial segment. The following high-resolution axial images were acquired using cardiac gated, fat saturated, blood suppressed fast spin echo: T_1 -weighted, STIR and dual echo T_2 /PD-weighted images. An echo planar imaging sequence was used to obtain diffusion-weighted images (DWI). Histology (haematoxylin and eosin, elastic Van Geison and Nile red) was collected and used to assist the manual segmentation by an expert. The expert manually traced the carotid inner and outer wall contours and delineated hemorrhage, lipid and calcium regions.

A statistical pattern recognition system was designed to automatically detect the soft plaque. First, all vessel wall images were registered to each other and normalized. For each location, image, textural, and morphological properties were calculated. Finally a supervised linear discriminant classifier, trained by example data, was used to detect the different plaque types in an unseen case. The system was evaluated using leave-one-out cross-validation.

The automatic plaque detection method was applied to each possible combination of the six MR sequences. Agreement between the automatic detection and the observer was defined on a per slice basis by rating the existence of soft plaque as either present or not. Then Cohen's kappa statistic was used to quantify the agreement between the automatic segmentation and the histology derived reference. The sequence combination offering the best agreement was then evaluated in more detail. The lesion-wise sensitivity, the proportion of actual soft plaque lesions which are correctly identified, and the precision, the fraction of identified soft plaque lesions that are true soft plaque lesions, were calculated.

Results: In total 100 slices, of which 48 contained soft plaque, were analyzed. The sequence combinations with kappa > 0.60 (substantial agreement) are shown in Figure 1. The STIR, DWI, and T_1 w images offer a high classification performance; the best results were obtained by using the T_1 w and STIR sequences. For this combination of sequences the lesion-wise sensitivity was 70%, and the precision was 72%.

Discussion and Conclusion: Experiments show that the automatic detection of unstable plaque is in good agreement with the histology assisted manual segmentation. The results also show that the STIR and DWI sequences show an improvement over the T_2 w and PDw sequences. Hence, automatic detection of soft plaque may be feasible by using a limited number of MR sequences, saving both MRI system and image analysis time.

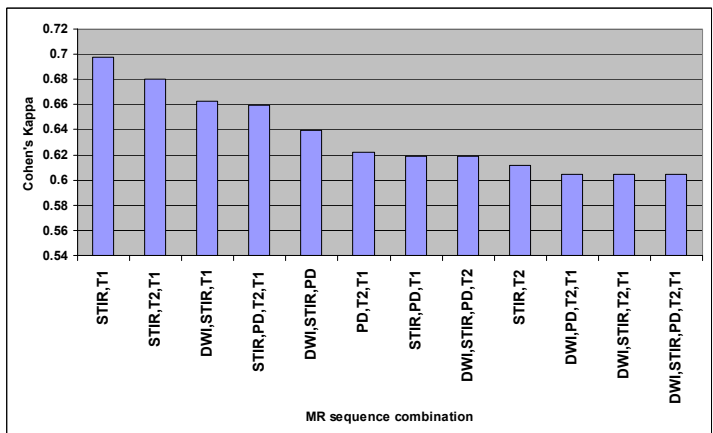


Figure 1: Agreement between the automatic and manual segmentation shown for sequence combinations with kappa > 0.60.

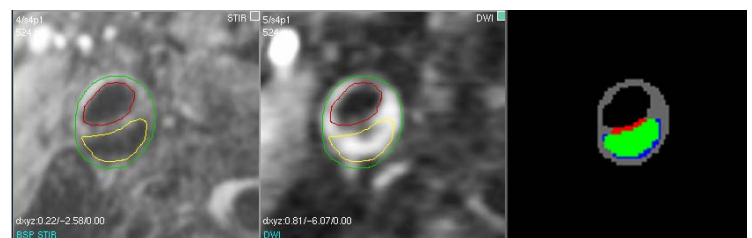

Figure 2: STIR and DWI images of a lipid lesion. Image at the right shows in green the overlap between the automatic and manual segmentation (red = false positive region, blue = false negative region).