

Analysis of Coronary Vein Motion: Implications for MR Coronary Vein Venography

P. J. Watson¹, J. D. Suever², and J. N. Oshinski¹

¹Radiology, Emory University, Atlanta, Georgia, United States, ²Biomedical Engineering, Georgia Institute of Technology

Objective

To quantify periods of low motion of the coronary veins during the cardiac cycle for planning coronary magnetic resonance venograms (cMRV).

Background

Whole-heart, navigator-echo gated, contrast-enhanced techniques can be used to acquire 3D magnetic resonance coronary venograms (cMRV) [1]. The cMRV can be used for planning lead placement in cardiac resynchronization therapy (CRT). However, cardiac and respiratory motion can degrade image quality. To reduce the effects of cardiac motion, it is desirable to acquire image data only during periods of low vessel motion, typically assumed to be during diastole [2]. The temporal location of the low motion period can be used to set the trigger delay in cMRV acquisitions, and the temporal length of the low motion period can be used to set the width of the acquisition window in cMRV studies. Previous studies have looked at coronary artery motion, but a similar analysis of the coronary veins has not been performed [3, 4].

Methods

The motion of the coronary sinus was tracked under the assumption that its movement is an indicator of overall coronary vein motion. SSFP cine images in the vertical long axis orientation were acquired with 30 frames over the cardiac cycle on a Siemens Avanto 1.5T Scanner (Siemens Medical Solutions, Erlangen, Germany). 16 patients with ischemic heart disease (age: 57.1 ± 12.9 years) were studied. The centroid and cross-sectional area of the coronary sinus were computed for each frame. The periods of low motion were defined periods during which frame-to-frame displacement was less than 0.5 mm [3]. The temporal location and duration of the periods of low motion were determined as a percent of the cardiac cycle (%CC). Based on the ratio of each patient's systolic to diastolic duration, patients were classified into either *systolic* or *diastolic* dominant. The total displacement of the coronary sinus over each low motion period was also determined.

Results

The coronary sinus was well visualized in the VLA cine images in all patients. There were 5 systolic dominant patients and 11 diastolic dominant patients, Figure 1. In the *systolic* dominant group, the center of systolic low motion occurred at 49.1 ± 1 %CC with a duration of 24 ± 13 %CC. The *diastolic* dominant group had a diastolic period of low motion at 75.2 ± 3.5 %CC with a duration of 17.6 ± 7.2 %CC. The low motion periods showed an overall displacement of 0.8 ± 0.5 mm (range 0.1-2.7 mm). In general, the cross sectional area was larger during systole than during diastole.

Conclusion

Although the majority of patients had longer periods of low motion during diastole than during systole, about a third of the patients either had a very short diastolic period or lacked it completely. Patients' low motion periods should be categorized before imaging the coronary veins to ensure the correct period is being utilized. Although the frame-to-frame method can determine periods of low motion, it does not account for steady, drifting movement seen by the large overall displacements.

References

- (1) Bhat, et al., JMRI 2009.
- (2) Wang, Y., et al., Radiology 2001.
- (3) Johnson, K., et al., JCMR 2004.
- (4) Nezevat, R., et al., Magn Reson Med 2007.

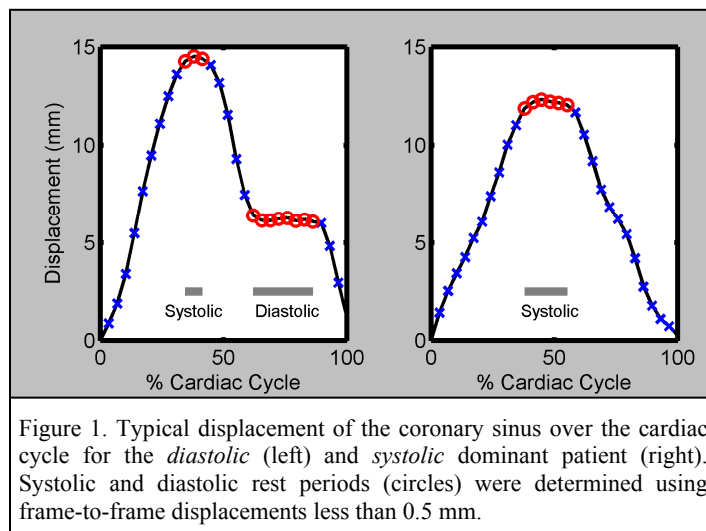


Figure 1. Typical displacement of the coronary sinus over the cardiac cycle for the *diastolic* (left) and *systolic* dominant patient (right). Systolic and diastolic rest periods (circles) were determined using frame-to-frame displacements less than 0.5 mm.