

Acute vs. Tonic Muscular Pain: Changes in Cerebral Blood Flow as Imaged by Arterial Spin Labeling

D. G. Owen^{1,2}, C. F. Clarke³, S. Ganapathy³, F. S. Prato^{1,4}, and K. S. St. Lawrence^{1,2}

¹Imaging Program, Lawson Health Research Institute, London, Ontario, Canada, ²Medical Biophysics, The University of Western Ontario, London, Ontario, Canada, ³Anesthesia and Perioperative Medicine, The University of Western Ontario, London, Ontario, Canada, ⁴Imaging, St. Joseph's Hospital, London, Ontario, Canada

Introduction: Findings suggest that the neural processing of acute pain, whether of muscular or cutaneous origin, recruits similar brain regions [1]. Applying functional imaging to prolonged stimuli (i.e., low task frequency) is more difficult, and the results of two positron emission tomography studies were inconsistent [2,3]. We have previously used arterial spin labeling (ASL) to determine the dynamics of neural activation associated with a muscular pain stimulus incorporating both acute and tonic phases [4]. The goal of the current study was to investigate the neural activation associated with purely tonic muscular pain. ASL was chosen for this purpose because it is well suited to stimulation paradigms with low task frequency [5].

Materials and Methods: A multi-slice, spiral ASL sequence was used to collect CBF images on a 3T magnet equipped with an 8-channel, receive only, phased array coil (GE medical systems) [6]. Twelve axial perfusion-weighted images were acquired every 6 s with an in-plane resolution of 3.75 mm and a slice thickness of 6 mm. Fifteen healthy male volunteers (aged 18-42, mean: 27±5) were imaged during 12 minutes of baseline (no pain) followed by 15 minutes of pain from the intramuscular infusion of hypertonic saline (HS) (5% NaCl) into the left forearm. To avoid acute pain responses, the stimulus did not include an initial bolus injection as in the previous study [4].

Results: Reported pain reached 6/10 approximately 5 min after the start of HS infusion. The tonic stimulus elicited significant CBF increases in bilateral insula, bilateral inferior frontal gyrus (IFG), and right middle frontal gyrus (MFG) (Fig. 1). ROI analysis of the insula showed that the purely tonic stimulus was associated with much smaller, gradual CBF increases that were maintained at low levels compared to the rapid CBF response elicited by a bolus injection of HS [4]. Levels of CBF increase in the insula overlapped with those from the tonic phase of our previous study (Fig. 2).

Discussion: Arterial spin labeling is well suited to prolonged pain models, and since CBF is measured directly, activation levels from different studies are easily compared. This study demonstrated that the neural activation associated with tonic pain is considerably different from that typically observed in studies of acute pain. In the tonic state, CBF increases were predominantly observed in bilateral insula with no activation observed in other 'pain-related' centers such as the anterior cingulate or thalamus. Bilateral insula activation is consistent with a PET study of tonic pain [2]. The relative increase in insular CBF was also considerably smaller than we previously observed following a rapid injection of HS, despite similar subjective pain ratings (Fig 2). A likely explanation is that the pain generated by the bolus injection elicited a strong emotional response (anxiety, distress); whereas our tonic pain stimulus did not and, as such, produced activation related more to pain sensation.

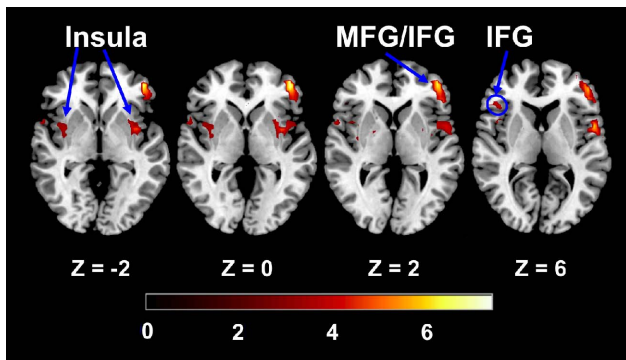


Fig. 1 Group activation maps: Areas of significant CBF increases during the HS infusion. Corrected for multiple comparisons (FDR, $p < 0.05$).

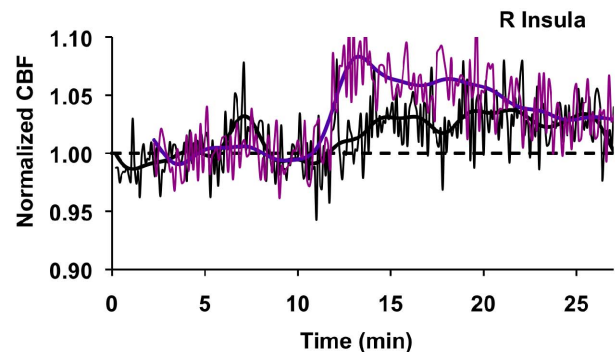


Fig. 2 Right insula time courses: CBF changes (relative to baseline) as a function of time in the right insula for the purely tonic stimulus (black) and the bolus stimulus (purple) (ref. 4). Smoothed and raw data shown.

References

- (1) Niddam & Hsieh, *J Chin Med Assoc* 2009;72(6):285-93.
- (2) Schreckenberger et al., *Neurology* 2005;64(7):1175-83.
- (3) Thunberg et al., *Eur J Pain* 2005;9(2):185-94.
- (4) Owen et al., *Pain* 2009; doi:10.1016/j.pain.2009.10.003a.
- (5) Wang et al., *MRM* 2003;49(5):796-802.
- (6) St. Lawrence et al., *MRM* 2005;53(3):735-738.