

Diffusion Tensor Imaging of Brain White Matter Changes Across the Lifespan

C. Lebel¹, M. Gee¹, R. Camicioli², M. Wieler², W. Martin², and C. Beaulieu¹

¹Biomedical Engineering, University of Alberta, Edmonton, Alberta, Canada, ²Neurology, University of Alberta, Edmonton, Alberta, Canada

INTRODUCTION: Lifespan studies of the normal human brain provide the necessary link between the developmental processes of childhood and the degenerative processes of old age. Diffusion tensor imaging (DTI) has been used in many studies to evaluate white matter changes at either end of the age spectrum, but only a handful of studies have examined brain structures across the lifespan, including the corpus callosum^{1,2} and the uncinate fasciculus³. The purpose of this study was to measure unique white matter tract trajectories across a wide age range (5-83 years) in a large number of healthy subjects (n=392) using DTI tractography.

METHODS: Subjects were 392 healthy volunteers (201f/191m) aged 5-83 years with no history of neurological/psychiatric disease or injury. All scans were performed on the same 1.5T Siemens Sonata scanner. DTI was collected using dual spin echo EPI, 35 or 40 3mm slices (no gap), image matrix 128x128 with 75% phase partial Fourier zero-filled to 256x256, TE/TR = 88 ms/6400 ms, b=1000 s/mm², 8 averages, 6 directions, ~ 6 minutes. Semi-automated, deterministic tractography was performed using previously described methods⁴ to delineate twelve major white matter tracts: the superior and inferior longitudinal fasciculi (SLF/ILF), superior and inferior fronto-occipital fasciculi (SFO/IFO), anterior and posterior limbs of the internal capsule (ALIC/PLIC), uncinate fasciculus (UF), cingulum (CG), fornix (FX), and genu, body, splenium of the corpus callosum (gCC, bCC, sCC). Fractional anisotropy (FA) and mean diffusivity (MD) were averaged for each subject over the entire tract; each voxel was counted only once. Curves were estimated separately for males and females initially, and combined where no significant differences existed. The equation used to model age changes was: FA (or MD) = C + A*age*e^{-B*age} + D*Sex. Age of peak FA and minimum MD values were determined for each tract.

RESULTS/DISCUSSION: FA and MD followed Poisson-type curves, with FA increasing from childhood to adulthood, then decreasing at a slower rate; MD followed an opposite trend, decreasing until adulthood, then increasing more slowly (Figure 1). All fitting parameters were highly significant for each tract (p<0.001). Peak FA values were achieved between 20-42 years and minimum MD values from 18-43 years. Tracts could be divided into groups based on when they reached their FA peak: early peaking (<25 years: FX, ILF, gCC, sCC), intermediate peaking (25-30 years: ALIC, IFO, SFO, SLF), and late peaking (>30 years: bCC, CG, PLIC, UF). MD groupings were similar for early (FX), intermediate (ALIC, bCC, gCC, IFO, ILF, sCC) and late minima (CG, PLIC, SFO, SLF, UF). The cingulum, IFO, and UF (all frontal lobe connections) underwent the largest percent increases of FA from 5 years to the peak (12-16%), while the ILF, IFO, and SLF dropped the most after the peak (9-11%). The CG, bCC, gCC, and sCC showed the largest MD drops before the minima (11-14%), while the bCC and FX gained the most after it (14-20%). Figure 1 shows three examples of FA curves and one MD curve. Small, but significant, sex differences were observed in the UF, bCC, and ILF for FA only, and the CG, PLIC, and SLF for FA and MD. Tractography has revealed development trends of FA and MD that are unique throughout the brain white matter. Frontal-temporal connections (CG and UF) demonstrate prolonged development and later reversals than other tracts, while the FX, sCC and gCC develop earliest and have the most prolonged FA declines and rising MD. A very wide age range and a large number of subjects make the identification of development trends such as these possible.

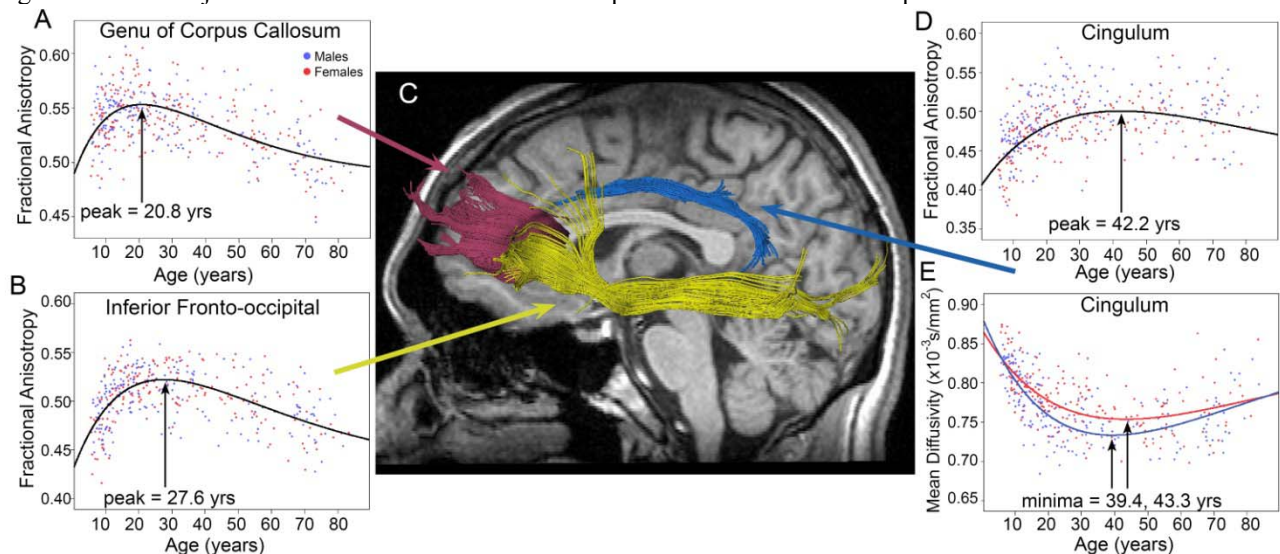


Figure 1: Age-related changes of fractional anisotropy (FA; panels A, B, D) and mean diffusivity (MD; panel E) are shown for three tracts representing early (genu; A), intermediate (inferior fronto-occipital fasciculus; B), and late development (cingulum; D, E). Panel C shows the tracts (genu-pink, inferior fronto-occipital fasciculus-yellow, cingulum-blue) in a healthy 22 year old male. Sex differences were significant for MD in the cingulum, so male and female curves are shown separately.

REFERENCES: 1.K. Hasan *et al.*, *Brain Res* **1249**, 91 (2009). 2. N. McLaughlin *et al.*, *Int J Dev Neurosci* **25**, 215 (2007). 3.K. Hasan *et al.*, *Brain Res*, (2009). 4. C. Lebel *et al.*, *Alcohol Clin Exp Res* **32**, 1732 (2008). 5.A. Pfefferbaum *et al.*, *Magn Reson Med* **44**, 259 (2000). 6. V. Schmithorst *et al.*, *Radiology* **222**, 212 (2002).