

In vivo measurement of cortical anisotropy by diffusion-weighted imaging correlates with cortex type

A. Anwander¹, A. Pampel¹, and T. R. Knösche¹

¹Max Planck Institute for Human Cognitive and Brain Sciences, Leipzig, Germany

Introduction: Microscopic analysis of the cortex shows variable microstructure in different functional-anatomical areas. Cortical areas with large pyramidal cells, which are oriented in normal direction with respect to the folded cortical surface, as in the motor cortex, might show radial anisotropy in high resolution DTI scans. The dominant direction should differ from other cortical areas with less dominant cell structure as the primary somato-sensory cortex. First evidence for cortex anisotropy measured by DTI was shown in vivo [1] and in a post mortem study [2]. In this study we analyze the cortical anisotropy with a new radially coefficient and test for the first time, if the principal diffusion direction depends on the type of the cortex.

Methods:

Imaging: We acquired high-resolution diffusion-weighted images (DWI) on a Siemens 3T whole body MR scanner (Trio a TIM system) using 32 channel phased array head coil (Siemens, Erlangen, Germany). DWI images were acquired with 1.5mm isotropic resolution (60 directions, $b=1000\text{s/mm}^2$, GRAPPA/3, NEX=3) from six subjects. The data was corrected for subject motion and registered to the T1 anatomy (1mm isotropic). The diffusion tensor and fractional anisotropy (FA) was computed for each voxel.

Directional analysis: The Cortex is masked using the registered T1 image and the main diffusion direction was compared to the cortex normal direction. This was done by color mapping of the scalar product of main diffusion direction and normal direction of the folded cortical surface (radiality index).

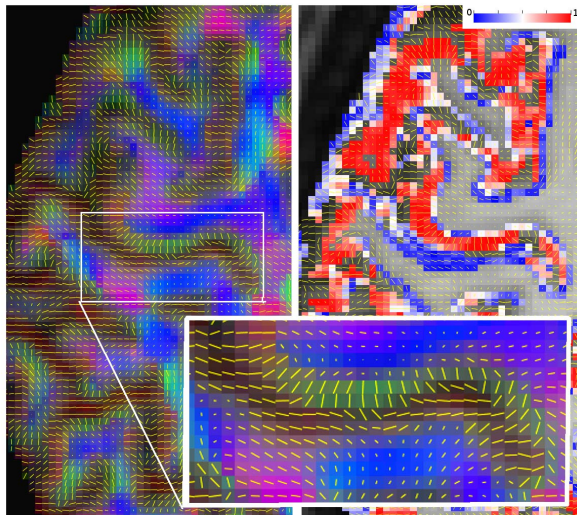


Fig 1: Axial slice of the main diffusion direction overlaid on the color coded FA map (left) and the radiality index (right); red: high radiality; blue: tangential orientation; zoom in on left precentral sulcus with motor- and somatosensory cortex.

Results:

The DTI images showed non-zero anisotropy with fractional anisotropy (FA) values ranging from 0.05 to 0.25. The measured diffusion tensor was oriented in normal direction with respect to the cortical surface at the crown of most gyri and in a dominant number of sulcal walls (Figure 1).

The deep fundi did not show this clear radial direction. Computation of the radiality coefficient revealed a correlation of this measure with the cortex type. Motor cortex and many prefrontal areas showed strong radiality whereas somato-sensory cortex and parietal cortical areas showed mainly tangential diffusion dominance and also lower FA values. Figure 3 displays the radiality coefficient a shrunk surface of the brain overlaid on the T1 anatomy.

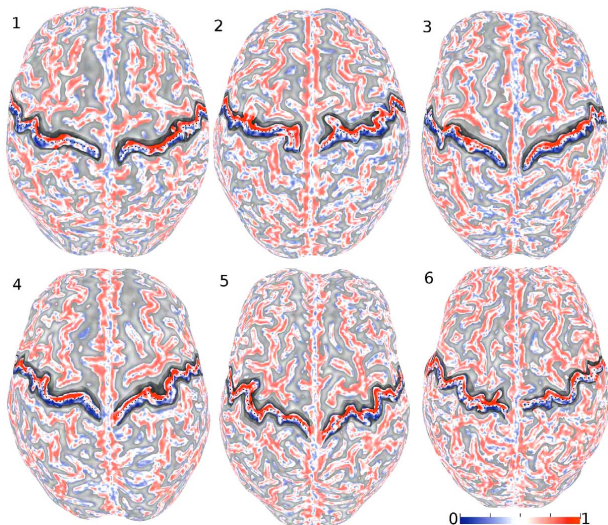


Fig 3: Group comparison of the gray-matter diffusion radiality index for 6 subjects. All subjects show a high radiality in the motor cortex and a mainly tangential diffusion orientations in the somatosensory cortex. The central sulcus is indicated by the dotted line.

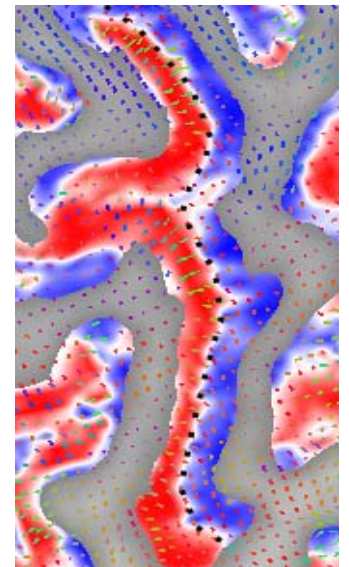


Fig 2: Diffusion radiality index in the precentral sulcus. Strong radiality is detected in the primary motor cortex.

Conclusions:

High resolution DTI in combination with parallel imaging and a phase array head coil acquisition system opens a new view on whole brain cortex anisotropy in vivo. We showed consistent radial orientation of the principal diffusion direction and non-zero anisotropy in large parts the human cortex. The proposed radiality index is sensitive to the cortex type and might open a new way to in vivo cortex parcellation. Diffusion in the motor cortex with large pyramidal cells is mainly radially oriented while diffusion in the somato-sensory cortex is dominated by a tangential orientation. This might relate to a strong wiring between neighboring cortical areas. The relation of the cortical thickness and the absolute FA value to the diffusion radiality remains to be analyzed.

References: [1] Heidemann, et al. ISMRM 2009 #2403, [2] McNab, Neuroimage 2009, [3] Descoteaux, IEEE-TMI 2009.