

Simultaneous Optical Tomography (OT) and fMRI with and without Task Activation

J. Mehnert^{1,2}, C. Schmitz^{2,3}, H. E. Möller¹, H. Obrig^{1,2}, and K. Müller¹

¹Max Planck Institute for Human Cognitive and Brain Sciences, Leipzig, Germany, ²Berlin Neuroimaging Center, Charité University Hospital Berlin, Berlin, Germany, ³NIRx Medizintechnik GmbH, Berlin, Germany

INTRODUCTION

Correlation analysis of low-frequency fluctuations in blood-oxygen level dependent (BOLD) fMRI data is known to yield functional connectivity maps. The procedure, also referred to as 'resting-state connectivity', does not rely on a specific task performance and has recently been successfully applied to optical tomography (OT) data [1]. One of the limitations of OT is the low spatial resolution. To overcome this limitation, dense probe arrays had been used in the above pioneering study. However, full head coverage is desirable in order to avoid that analysis is constrained to specific networks. Here, we assess whether a sparser topographical sampling still yields results that are comparable to the 'gold standard' of resting-state network assessment, i.e. fMRI. In a first step, we used a subset of optical fibers in a typical grid (2-3cm inter-optode distance) covering both motor cortices. Such a grid can be extended to whole head coverage, without overly interfering with the subject's comfort. We combined OT with concurrent fMRI measurements to cross-validate our resting-state data analysis.

METHODS

The task consisted of 600 s scanning without task activation (eyes open) followed by a block-design finger-tapping task (25 trials, 10-s tapping, 10-s rest, left and right tapping in different sessions). The latter was included to functionally define a seed region of interest (ROI) in the motor cortex. fMRI data acquisition was performed on a whole-body 3T MAGNETOM TIM Trio scanner (Siemens, Erlangen, Germany) equipped with a transmit/receive birdcage head coil. A gradient-echo echo-planar imaging (EPI) sequence was used with an echo time, TE = 30 ms, and an acquisition bandwidth, BW = 116 kHz. The acquisition matrix was 64x64 with a field of view (FOV) of 19.2 cm, resulting in in-plane voxel dimensions of 3 x 3 mm². The slice thickness was 4 mm with an inter-slice gap of 1 mm. In the scan without task activation, we acquired 300 volumes (30 axial slices, repetition time, TR = 2 s, flip angle 78°). In the finger-tapping experiments, 510 volumes were acquired (15 coronal slices through the motor system, TR = 1 s, flip angle 62°). Optical data was acquired with a NIRScout 816 (2 wavelengths, 8 sources, 16 detectors, sampling frequency 6.25 Hz) produced by NIRx Medizintechnik GmbH, Berlin, Germany (Figure 1).

RESULTS

Motor activation was analyzed using a general linear model (GLM) approach yielding highly consistent results in both fMRI and OT (Figure 2). Activation maxima were selected as seed ROIs for the subsequent correlation analysis. The inter-hemispheric correlation between motor-cortices was revealed in both fMRI and OT data based on a resting-state connectivity approach. The magnitude of the correlation depends on the particulars of the data preprocessing.

CONCLUSIONS

The current study establishes the feasibility of resting-state data analysis for topographical optode arrangements and thereby opens a perspective of whole-head measurements with OT. Due to its easy applicability, OT may develop into a tool for resting-state connectivity studies in subjects or patients not suited for fMRI experiments. The enquiry into changes of resting-state connectivity during task performance and training may also profit from such an approach.

REFERENCE: [1] White BR, Neuroimage 47, 1 (2009).




Figure 1. Near-infrared spectroscopy (NIRS) sensors as worn by the subject inside the fMRI head coil. A standard 128-positions EEG cap is used to position the sensors on the head.

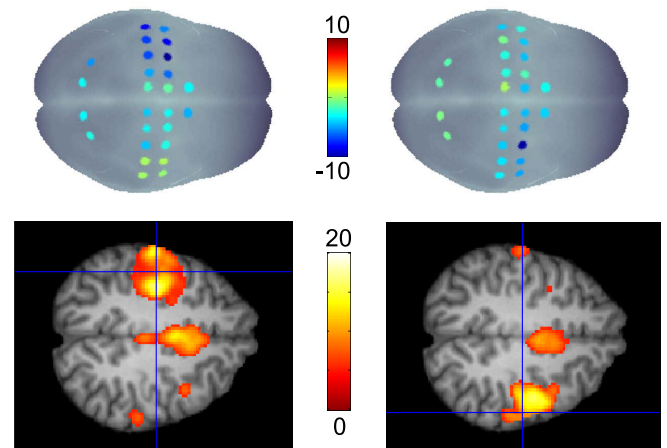


Figure 2. Statistical results of OT (top row) and fMRI (bottom row) using right and left finger tapping. Note that high activation is coded in blue (negative t-values) in the OT maps. The fMRI results show associated regions of the motor system ($p < 0.05$, corrected).