

## What is the optimum fMRI procedure with auditory stimulation?

K. Mueller<sup>1</sup>, T. Mildner<sup>1</sup>, T. Fritz<sup>1</sup>, J. Lepsien<sup>1</sup>, C. Schwarzbauer<sup>2</sup>, and H. E. Möller<sup>1</sup>

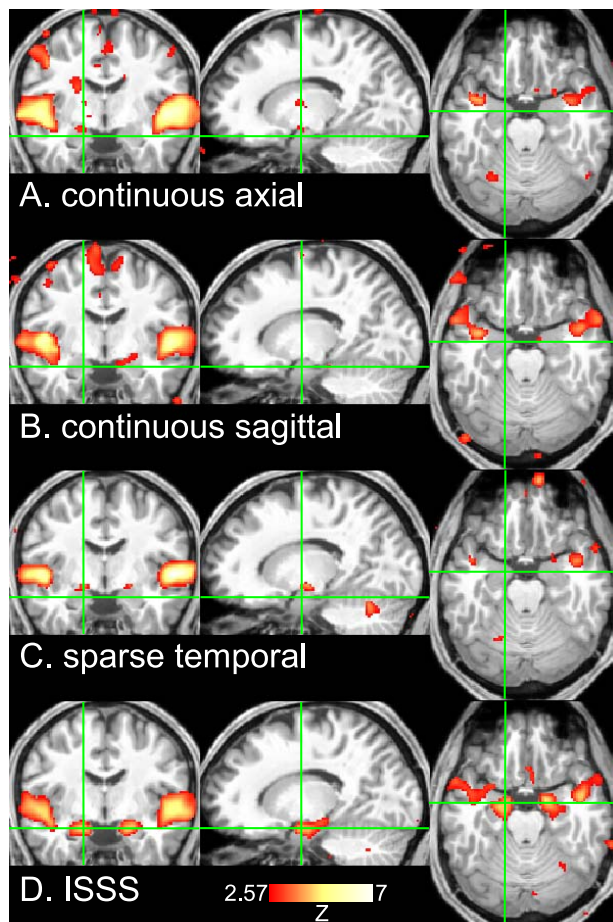
<sup>1</sup>Max Planck Institute for Human Cognitive and Brain Sciences, Leipzig, Germany, <sup>2</sup>Aberdeen Biomedical Imaging Centre, University of Aberdeen, United Kingdom

**Introduction:** Functional MRI in auditory experiments is a challenge because the scanning procedure produces considerable noise that can interfere with the auditory paradigm. The loud and unpleasant noise might mask the auditory presentation or interfere with stimuli designed to evoke positive emotions. Therefore, scanning protocols appear to be advantageous that allow interleaved auditory stimulation and image acquisition. The sparse temporal sampling (STS) technique utilizes a long repetition time (TR) in order to achieve a stimulus presentation in the absence of scanner noise. Although there are only a few volumes in the resulting data sets, studies have demonstrated remarkable results (1,2). A more recent development is the interleaved-silent steady-state (ISSS) technique, which provides a stimulus presentation during silence with a higher temporal efficiency (3).

To evaluate which protocol yields the optimum performance with auditory stimulation, we have compared the results of four different fMRI sessions of the same total acquisition time: continuous axial scanning, continuous sagittal scanning, STS, and ISSS.

**Methods:** All measurements were performed using a 3T whole-body scanner (MedSpec 30/100, Bruker BioSpin, Ettlingen, Germany) and a birdcage head coil. 20 volunteers (7 female, mean age=26.3 y, std=4.0 y) listened to a selection of pleasant instrumental music from the last four centuries (all major-minor tonal music) and their manipulated counterparts (reversed dissonant, unpleasant). Loudness levels of all stimuli were matched using RMS normalization. All pleasant and unpleasant stimuli had a length of 10 s and were presented in an alternating order.

In each subject, four sessions were acquired in randomized order using gradient-echo EPI sequences. A rectangular FOV of 16.5×19.0 cm<sup>2</sup> with an acquisition matrix of 66×76 (i.e., in-plane voxel size of 2.5×2.5 mm<sup>2</sup>) and a slice thickness of 3.5 mm was used throughout. In two sessions, 36 slices were acquired with axial or sagittal slice orientation, a TR of 2.5 s, and auditory stimulation presented during continuous scanning. In the remaining two sessions, STS and ISSS were used both with acquisition of 15 axial slices. For STS, a single volume was acquired within 1 s after the auditory stimulus which yielded a TR of 11 s. For ISSS, the TR was 1 s for both, the period of auditory stimulation during which the magnetization was kept in a (silent) steady-state and the subsequent acquisition of 5 volumes. The total duration of each session was 12.5 minutes, which was adjusted by the choice of the corresponding number of repetitions.



The data were analyzed following realignment, normalization, and spatial smoothing using SPM8. The normalization was performed into the MNI space using the unified segmentation approach based on individual high-resolution T1-weighted anatomical images. The resulting isotropic voxel size was 2 mm. After normalization, a spatial Gaussian filter of 8-mm FWHM was applied. Furthermore, a temporal high pass filter was used in order to remove drifts in the signal. The cutoff frequency was chosen conservatively using the double length of a full pleasant-unpleasant cycle, i.e. the cutoff frequency was 1/40 Hz for the continuous image acquisition. The statistical analysis was done using the software package Lipsia (4), which supports the analysis of ISSS data with a non-uniform sampling time in the general linear model. The group analysis consisted of a one-sample t-test across the contrast images of all subjects that indicated whether observed pleasant-unpleasant differences significantly differed from zero.

**Results & Discussion:** As expected (cf. Fig. 1), we observed strong pleasant-unpleasant differences in the left and the right auditory cortex which indicate that the primary auditory cortex is stronger involved with pleasant than with unpleasant sounds (5). More subtle activations in the amygdala or hippocampus could not reliably be detected by neither continuous axial nor continuous sagittal scanning. For ISSS, strong bilateral activations were found (see green cross-hair in Fig. 1). These activations persisted even after correcting for multiple comparisons ( $p < 0.05$ ). Although only 68 volumes were acquired using STS, a few significant voxels appeared in this region when using an uncorrected threshold of  $p < 0.005$  on a voxel-level.

To summarize, the ISSS technique was suitable for detecting rather subtle activations induced by auditory stimuli. Regarding the interference with scanner noise, the STS session exhibited a similar performance, but did not show sufficient sensitivity due to the small number of volumes per unit time (3). A strong drop in sensitivity was found for the sessions that used stimulus presentation during continuous scanning. It should be noted that the latter finding strongly depends on both sequence implementation and gradient performance.

**Figure 1.** Coronal, sagittal, and axial slices showing the group analysis of the pleasant-unpleasant contrast ( $p < 0.005$  uncorr.) using four different fMRI sessions. When using ISSS (bottom row), both the left and the right amygdala/hippocampus clusters survive the correction for multiple comparisons ( $p < 0.05$ ).

**References:** [1] Hall D; Hum Brain Mapp 7, 213 (1999). [2] Gaab N; Neuroimage 19, 1417 (2003). [3] Schwarzbauer C; Neuroimage 29, 774 (2006). [4] Lohmann G; Comp Med Imag Graph 2, 449 (2001). [5] Koelsch S; Hum Brain Mapp 27, 23 (2006).