

Pharmacological analysis in experimental lung fibrosis performed by MRI

A. L. Babin¹, C. Cannel¹, C. Gerard¹, C. P. Page², and N. Beckmann¹

¹Global Imaging Group, Novartis Institutes for BioMedical Research, Basel, BS, Switzerland, ²Sackler Institute of Pulmonary Pharmacology, King's College, London, SE1 1UL, United Kingdom

Introduction:

Edema and collagen deposition are processes involved in the inflammatory response, which are fundamental to wound-healing [1]. Despite their diverse symptoms and etiologies, asthma and chronic obstructive pulmonary disease, as well as many other forms of pulmonary pathologies, share the common features of airways remodeling and excess collagen deposition [2]. The mechanisms behind such changes are not entirely clear. Furthermore, the relationship between inflammation and fibrosis is complicated by the fact that although fibrosis may develop concomitantly or subsequently to inflammation, the real causal relationship between the two remains unknown [2,3].

A single intra-tracheal (i.t.) instillation of bleomycin (BLM), an antineoplastic antibiotic, is commonly used to induce experimental lung fibrosis in rodents [4]. In the present work the development of lung injury in response to BLM has been tracked non-invasively with MRI in rats over an extended time course. The nature of the insult has herein been investigated using the topically and orally active steroids, budesonide and dexamethasone, respectively.

Materials and Methods:

Animals: Male Sprague-Dawley (SD) rats weighing 280-320 g were supplied by SPF Harlan CPB.

BLM administration: Rats were anesthetized (4% isoflurane; Abbott, Cham, Switzerland) in a chamber and then treated with BLM hydrochloride (Euro Nippon Kayaku GmbH, dissolved in 0.2 ml saline) [3] administered i.t. before the bifurcation of the carina. BLM was dosed at 1, 3, 4, or 5 mg/kg on day 0 of the experiment.

Steroid treatment: Budesonide (Sigma, St Louis, MO; 1, 3 or 9 mg/kg) or dimethyl sulfoxide vehicle (DMSO: 4% DMSO/saline v/v) was administered i.t. at days 6 and 13 post BLM. Dexamethasone (Sigma; 0.1 and 0.5 mg/kg) or its vehicle (saline) was given orally from days 3 to 5 after BLM.

MRI: Rats were anesthetized with isoflurane (2.0%) in a mixture of O₂/N₂O (1:2), administered via a face mask. Measurements were carried out with a Bruker Biospec 47/40 system. A gradient-echo sequence was used throughout the study for detecting fluid signals (TR = 5.6 ms; TE = 2.7 ms; FOV = 6x6 cm²; matrix = 256x128; slice = 1.5 mm; 45 image averages with an interval of 530 ms between each image acquisition). Neither cardiac nor respiratory triggering was applied, and rats respired spontaneously.

Image analysis: The volume of the MRI signals in the lung was quantified by applying a semi-automatic segmentation procedure as described previously [5].

Results and Discussion:

The effect of acute steroid treatment at two different time points following BLM was used to investigate pharmacologically the nature of the induced lung injury. BLM (5 mg/kg i.t.) produced a significant and early lung response, as detected by MRI at day 6 (fig. 1a). Animals were then treated acutely with budesonide at day 6. When the rats were remeasured 24 h later, signal volumes were significantly attenuated in all budesonide groups (fig. 1b). Since budesonide is a potent anti-inflammatory compound known to be active topically, the reduction in signal volumes in the steroid groups suggested a significant resolution of inflammation not seen in the vehicle group. A second budesonide administration at day 13 revealed a smaller percentile reduction in signal, suggesting a less pronounced inflammation resolution. The fact that no complete resolution of signals has been observed despite the application of high budesonide doses indicate the presence of excess collagen deposition related to fibrosis that was not resolved by the steroid treatment. Anti-inflammatory drugs do not necessarily possess anti-fibrotic properties, and conventional therapeutic drug treatments such as corticosteroids, immunosuppressives, and cytotoxic agents possess limited therapeutic benefit as anti-fibrotics or fibrolytics [7]. These observations are important because they help to illuminate a time line for inflammation and fibrosis in the rat BLM model using non-invasive means of assessment.

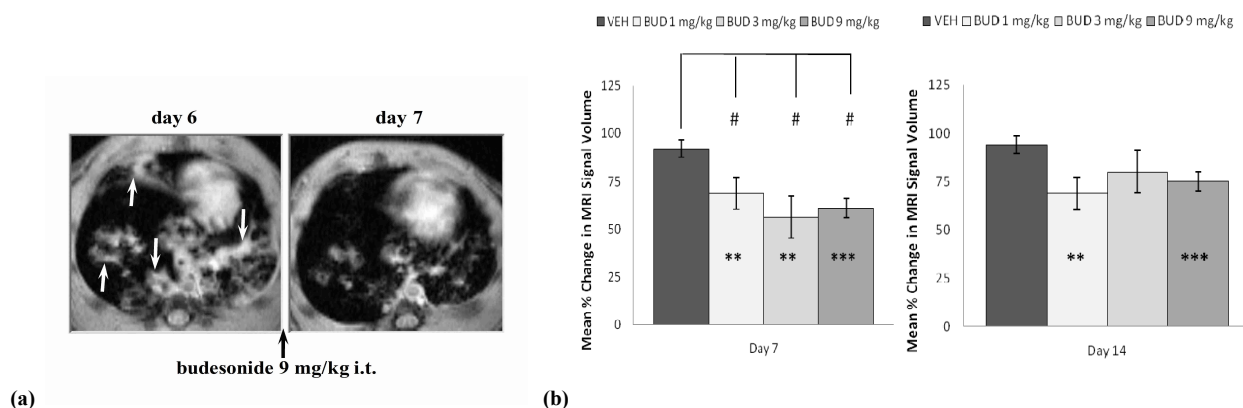


Fig. 1 – (a) Transverse MRI scans acquired at week 1 post BLM (5 mg/kg i.t.). Prominent inflammatory signals were detected at day 6 (arrows), but were reduced after budesonide. **(b)** Percentile MRI signal volume (\pm sem, n=6 rats/group), calculated taking as 100% the signal volume from each individual animal at respectively days 6 and 13 (before budesonide). The steroid or vehicle has been administered i.t. at days 6 and 13 post BLM. Compared to preceding 24 h: **P<0.01, ***P<0.001. Compared to vehicle: #P<0.05.

A second example, reproducing a protocol from the literature [8], was a short treatment with the steroid dexamethasone administered orally (0.1 and 0.5 mg/kg) from days 3 to 5 after BLM (1.2 mg/kg i.t.). This experiment was chosen for validation purposes and to illustrate that timing for initiation of treatment may be crucial for steroids to exert an anti-fibrotic effect. Measurements at day 7 revealed a significant reduction in lung signals in the dexamethasone group compared to vehicle-treated rats. Histology revealed reduced inflammation and fibrosis in the lungs of dexamethasone-treated rats. Our results are consistent with published data demonstrating that a 3 day course of dexamethasone treatment initiated 3 days after BLM-induced lung injury reduced lung cell proliferation and collagen deposition [8].

The present results indicate the value of MRI for *in vivo* pharmacological studies regarding experimental lung fibrosis. Experimental studies in animals have usually examined the effects of treatments starting before or at the time of lung injury. However, this is not representative of the human condition as treatment only begins after disease has been established. Since timing of treatment initiation is critical in this chronic model, the fact that repetitive measurements are feasible with MRI opens new avenues in testing compounds as the responses at several time points during the course of treatment can be easily compared.

1. Meneghin A, Hogaboam CM. J Clin Invest 2007; 117:530-538.
3. Wynn TA. J Clin Invest 2007; 117:524-529.
5. Beckmann N et al. Magn Reson Med 2001; 45:88-95.
7. Chaudhary NI et al. Am J Respir Crit Care Med 2006; 173:769-776.

2. Chua F et al. Am J Resp Cell Mol Biol 2005; 33:9-13.
4. Izbicki G et al. Int J Exper Pathol 2002; 83:111-118.
6. Hoshino M et al. J Allergy Clin Immunol 1999; 104(2 Pt 1):356-363.
8. Dik WA et al. Thorax 2003; 58:765-771.