

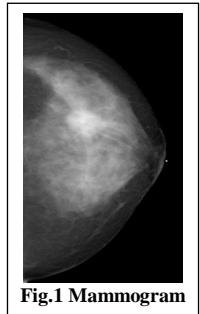
Exclusion of Skin for Measurement of Fibroglandular Breast Density on 3D MRI

K. Nie¹, D. Chang¹, J-H. Chen^{1,2}, C-C. Hsu², T-C. Shih^{1,3}, H. Nguyen¹, M. Lin¹, O. Nalcioglu¹, and M-Y. L. Su¹

¹Tu & Yuen Center for Functional Onco-Imaging, University of California, Irvine, Irvine, CA, United States, ²Department of Radiology, China Medical University, Taichung, Taiwan, ³Department of Medical Radiology Technology, China Medical University, Taiwan

Introduction:

It is known that an increase of mammographic density is associated with increased cancer risk; however, it is very difficult to measure small changes unless the measurement technique is highly accurate. A recent paper by Kopans has investigated the possible variation arising from projection properties of the mammogram, and suggested that researchers who are interested in exploring tissue density and breast cancer risk need to start thinking three dimensionally [1]. Evaluating breast density based on 3D MRI is a promising alternative approach. There are only a few studies published in the literature reporting MRI-based techniques to quantitatively measure breast density. Two major procedures are needed: 1) segmentation of the breast from the body; and 2) segmentation of fibroglandular tissue from the fatty tissue within the breast. However, none of these published studies have considered the skin effect. Skin exhibits hypointense signals compared to fatty tissue on breast MRI, and if not properly handled the skin can be misclassified as fibroglandular tissue. On the contrary, skin does not affect the measurement of density on mammogram, as shown in Fig. 1. For every pixel, the x-ray is equally attenuated by two layers of skin and could be ignored in the density measurement. The purpose of this work was to investigate the impact of skin on MR-based density measurement. Specifically we evaluated the density measured with and without skin exclusion, also the relationship between skin volume and breast volume was studied.



Methods:

50 subjects with a broad spectrum of breast densities enrolled from Mar. 2005 to June 2006 were included in this study. MRI was acquired using a Phillips Eclipse 1.5T scanner. Only the normal breast was analyzed. The breast and fibroglandular tissue were segmented using our previously published methods based on fuzzy c-means (FCM) algorithm [2]. T1-weighted images without fat-sat was used for analysis (Fig. 2a). As shown in Fig. 2b, if the skin was not excluded, the FCM analysis would reveal a layer on the breast boundary on each slice, which would then be categorized into the same cluster as fibroglandular tissue. Dynamic searching was implemented along the direction perpendicular to the breast-air boundary, based on the change of gray level gradient. The upper border of the skin was determined when the negative gradient from skin to air was found; and the lower border was determined when the positive gradient from skin to fatty tissue was found. Up to a maximum of 3 pixels between these two borders were defined as skin. Fig. 2c shows the 3D view of the segmented skin. For women with fatty breasts, the skin volume could be comparable to or even greater than fibroglandular tissue, as shown in Fig. 2d. As such, skin exclusion is a necessary step to accurately measure the density, especially for fatty breasts. However, as the contrast between skin and breast or air is not strong, skin segmentation is a difficult task. Therefore, we also investigated the correlation between the volume of the skin and the breast using linear regression models, aiming to provide an estimation of the skin volume based on breast volume.

Results:

Fig. 1 shows segmentation results of 3 cases. Case I is a fatty breast, Case II has moderate density, and Case III is an extremely dense breast. The measured breast volume, fibroglandular tissue volume, skin volume, and the percent density with and without skin are listed in Table 1. These 3 cases had comparable breast volume (I: 607 cm³, II: 717 cm³, III: 510 cm³) and skin volume of 50, 58, and 45 cm³. If the skin is not excluded and misclassified as fibroglandular tissue, the percent density will be overestimated. For the fatty case, the fibroglandular tissue volume was 30 cm³ and the percent density of 5% (30/607). If the skin was not excluded, the percent density was 13.2% (80/607), resulting in a large error. The linear regression model was built to provide estimation of skin volume based on the breast volume. Model-1 used the original data: Skin Volume=0.03*Breast Volume+39. The linear model could explain 66% (adjusted R-square) of variation of the correlation. Model-2 used transformed data, square root of the skin volume vs. the cubic root of the breast volume (equivalent adjusted radius): (Skin Volume)^{1/2}=0.8*(Breast Volume)^{1/3}+3.6. Fig. 3 shows the correlation of 50 cases using Model-2. This model had improved correlation and could explain 0.76 (adjusted R-square) of the variation.

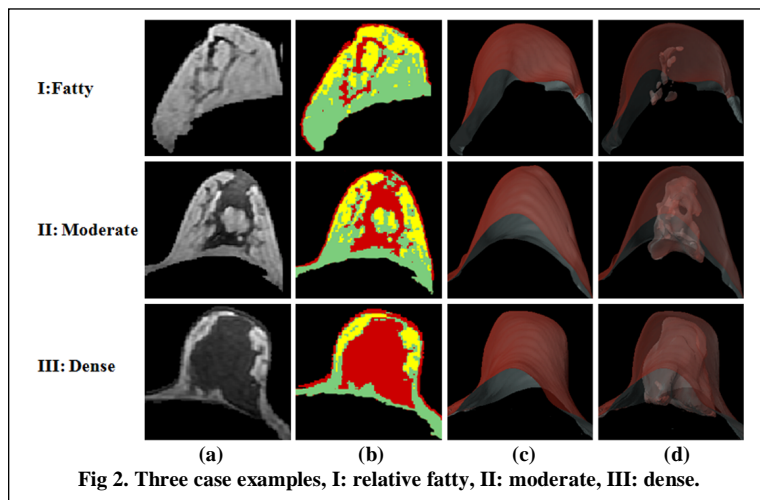


Fig 2. Three case examples, I: relative fatty, II: moderate, III: dense.

Table 1. Results of 3 examples on Fig.2

	I	II	III
Breast Volume (cm ³)	607	717	510
Fibro Volume(cm ³)	30	91	182
Skin Volume(cm ³)	50	58	45
Density w/o skin (%)	5.0	12.7	35.7
Density with skin (%)	13.2	20.8	44.5

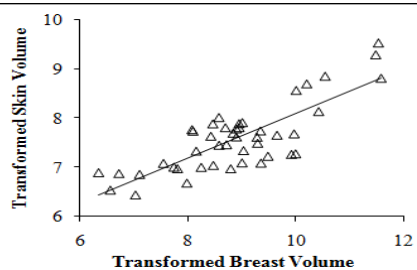


Fig 3. Relationship between skin vs. breast volume

Discussion:

Breast MRI provides strong soft tissue contrast, and three-dimensional coverage of the entire breast, and thus may provide detailed information for density measurement. However, since many images need to be processed, a consistent and reliable method is key for success. We have shown that if the skin is not excluded and is misclassified as fibroglandular tissue, this would result a large error in the density measurement. We also provided two models that could potentially be used to estimate the skin volume based on breast volume. This may be particularly helpful when the image contrast of the skin is not strong and can not be accurately segmented. If a reliable quantitative analysis method is available, it can be applied to measure the small changes after a women starting chemoprevention, to evaluate her benefit in terms of reducing breast density, thus cancer risk. Conversely, it may be applied to evaluate the increase of density after starting hormonal replacement therapy, to evaluate the increased risk. The MRI-based method has a high potential to measure small changes, provided that the effect of skin is properly handled.

References: [1] Kopans. Radiology 2008;98(17):1204-14. [2] Nie et al. 2008 ISMRM proceedings, program #3163, or Med Phys. 2008 (in press).

Acknowledgement: This work was supported in part by NIH CA90437 and CCRP 9WB-0020 and 14GB-0148.