

Diffusion weighted MRI in assessment of renal masses

K. Sandrasegaran¹, F. M. Akisik¹, C. P. Sundaram², M. P. Rydberg¹, C. Lin¹, and A. M. Aisen¹

¹Radiology, Indiana University School of Medicine, Indianapolis, IN, United States, ²Surgery, Indiana University School of Medicine, Indianapolis, IN, United States

Purpose: To assess the value of diffusion-weighted imaging (DWI) using 1.5 T MR scanner in differentiating renal masses.

Methods: This retrospective study measured the apparent diffusion coefficients (ADC) of renal masses. The diffusion sequence is given in table 1. Patients also had T1-weighted post-gadolinium 3-dimensional gradient echo (TR/TE (ms), flip angle: 4.85/2.48, 12⁰) with 10-20 ml of intravenous gadobenate dimeglumine. All malignant lesions had surgical pathology, with histological subtyping and nuclear (Fuhrman) grading for clear cell cancer. All benign lesions were stable without treatment for a minimum follow up of 12 months and did not show an enhancing mural nodule. In patients with multiple cystic lesions, ADC values of up to two lesions (> 1.5 cm in size) from each kidney were determined. ROC analysis was used to find the best cut-off values for differentiating renal masses using ADC values.

Results: ADC values of benign (3 abscess, 31 cysts) and malignant (17 clear cell, 5 papillary, 1 chromophobe and 2 transitional cell cancer) lesions were measured in 20 and 22 patients, respectively (Figure 1). There was no significant difference in age and gender of patients with benign and malignant lesions. The malignant lesions were larger than benign lesions (mean diameter of 4.2 vs. 2.6 cm, p=0.01, t-test). The ADC value of all benign lesions were significantly higher than malignant lesions (mean ADC of 272 vs. 188 x 10⁻⁵ mm²/s, p<0.0001, t-test). ADC of benign cysts (Bosniak I and II, n=31) were significantly higher than cystic renal cancer (Bosniak type IV, n=7) (mean ADC of 277 vs. 202 X 10⁻⁵ mm²/s, p<0.001). There was no significant difference between ADC of clear cell and non-clear cell malignant neoplasm (mean ADC of 185 vs. 197 x 10⁻⁵ mm²/s, p=0.18). The ADC of high-grade clear cell cancers (Fuhrman grades III, IV) tended to be lower than low-grade clear cell cancers (Fuhrman grades I, II) (mean ADC of 177 vs. 195 x 10⁻⁵ mm²/s, p=0.12). Best ADC cut off values are given in Table 2.

Conclusion: ADC measurements obtained with DWI at 1.5 T may aid in the differentiation on renal masses, particularly benign from malignant cystic lesions. Further research is required if DWI will be clinically useful in determining treatment of renal masses.

Table 1. DWI sequence

MRI Sequences	TR (ms)	TE (ms)	Flip angle	Slice thickness / gap (mm)	Matrix
DWI SE-EPI axial	1400-1600	52-62	90	6 / 2	192 X 115

SE EPI: Single shot echo planar imaging, breath-hold, NEX 2, FOV 36-40 cm, rec bandwidth = 1736 Hz/pixel b values of 0, 50, 400 sec/mm², GRAPPA acceleration factor of 2

Table 2. The best ADC cut-off values for differentiating various types of renal masses.

	Best Cut off *	Sensitivity #	Specificity #
All malignant vs. All benign	<=218	96 (79.6-99.3)	94 (80.3-99.1)
Clear cell vs. Non-clear cell cancer	<=189	65 (38.4 - 85.7)	63 (24.7 - 91.0)
High-grade vs. Low-grade clear cell cancer	<=187	80 (44.4 - 96.9)	71 (29.3 - 95.5)
Bosniak IV vs. I,II cystic masses	<=222	100 (58.9 - 100.0)	87 (70.1 - 96.3)

*: ADC values in 10⁻⁵ mm²/s

#: 95% confidence intervals in parenthesis

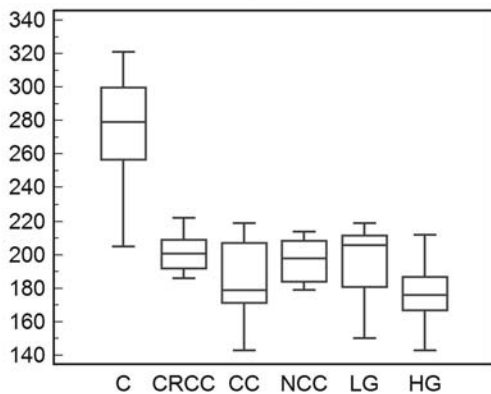


Figure 1: Box-and-whisker plot. Boxes represent the interquartile range. Whiskers represent range of all values. Horizontal line within box is the mean. Y-axis gives ADC values in 10⁻⁵ mm²/s
C = Benign Cyst
CRCC = Cystic renal cell cancer
CC = Clear cell cancer
NCC = Non-clear cell cancer
LG = Low-grade CC
HG = High-grade CC