

# Coronary Artery Distensibility Assessed by 3.0 T Cardiac MRI

S. Kelle<sup>1</sup>, A. G. Hays<sup>1</sup>, G. A. Hirsch<sup>1</sup>, G. Gerstenblith<sup>1</sup>, R. G. Weiss<sup>1</sup>, and M. Stuber<sup>1</sup>

<sup>1</sup>Johns Hopkins University, Baltimore, Maryland, United States

## INTRODUCTION

Atherosclerotic changes in the coronary artery are associated with impaired coronary vessel wall distensibility. Although non-invasive quantification of central aortic distensibility is possible by cardiac MRI (1), only intravascular ultrasound (IVUS) invasive measurements of coronary distensibility have been reported until now (2,3). We sought to test the hypotheses that coronary artery distensibility can be quantified non-invasively with 3.0 T coronary MRI and that differences can be detected between healthy and coronary artery disease (CAD) subjects.

## METHODS

Twenty-six healthy, adult subjects (14 male, mean 32±11 years) and nineteen patients with coronary catheterization documented CAD (11 male, mean 57±6 years) were studied on a commercial whole-body MR imaging system (Achieva 3.0 T; Philips, Best, NL). MR angiography of the right coronary artery (RCA); left coronary artery (LAD) and/or left circumflex artery (LCX) was performed with a navigator-gated free-breathing and ECG-triggered, T2-prepared, 3D, segmented k-space, gradient-echo imaging sequence. In each subject, the proximal segment of the RCA; LAD and/or LCX was then imaged in cross-section using cine spiral MRI for area measurements (Figure 1). MRI parameters were: echo time (TE)=1.5ms, radiofrequency (RF) excitation angle=20° and spectral spatial excitation, breath-hold duration~14-24sec, acquisition window =10ms, repetition time (TR)=14ms, 21 spiral interleaves, spatial resolution (acquired/reconstructed) = 0.89x0.89x8.00mm<sup>3</sup>/0.69x0.69x8.00 mm<sup>3</sup>. Both the brachial blood pressure and the heart rate were recorded. Imaging was performed at a constant room temperature and after at least 20 minutes of rest in the magnet. In a subgroup of seventeen healthy adult subjects and 4 CAD patients, an ECG-gated, turbo-field-echo (TFE) cine scan was acquired during breath-hold to determine aortic distensibility. This scan was obtained at the level of the right pulmonary artery through the ascending thoracic aorta. Typical aortic MRI parameters were: echo time (TE)=3.2ms, radiofrequency (RF) excitation angle=15°, repetition time (TR)=5.3ms, spatial resolution (acquired/reconstructed) = 0.99x0.99x8.00mm<sup>3</sup>/0.79x0.79x8.00 mm<sup>3</sup>. Images were analyzed for cross-sectional area changes using full width half maximum (Cine version 3.15.17, GE, Milwaukee, WI, USA), and distensibility (mmHg<sup>-1</sup>) was determined as: [(end-systolic lumen area-mid-diastolic lumen area)]/(pulse pressure multiplied by the mid-diastolic lumen area) (4). Pulse pressure was calculated as the maximal pressure change during a cardiac cycle (2). Data are expressed as mean values ± one standard deviation. Student's unpaired t-tests were used to compare the change in coronary cross-sectional area between the healthy and coronary artery disease subjects. The relationship between coronary and aortic distensibility was evaluated using a linear regression. Statistical significance was defined as a two-tailed p value <0.05.

## RESULTS

Twenty-three volunteers and seventeen patients had adequate image quality for coronary area measurements. The mean pulse pressure product in healthy adults (62 ± 10 mmHg) was not significantly different from that in CAD patients (68 ± 10 mmHg), (p=0.054). The luminal area during mid-diastole was 10.5 ± 2.0 mm<sup>2</sup> for healthy subjects and 13.5 ± 3.8 mm<sup>2</sup> for CAD patients (p<0.01). At end-systole, the luminal area in healthy subjects was 11.7 ± 2.3 mm<sup>2</sup> and 14.2 ± 4.1 mm<sup>2</sup> in CAD patients (p=0.02). Coronary vessel area changed significantly between end-systole and mid-diastole in healthy controls (p<0.001), and in CAD patients (p=0.03). Coronary artery distensibility was significantly higher in healthy subjects, than in the CAD patients (2.4 ± 1.3 mmHg<sup>-1</sup>\*10<sup>3</sup>) vs. 1.0 ± 0.9 mmHg<sup>-1</sup>\*10<sup>3</sup> respectively, p=0.004 (Figure 2). We found no significant correlation between coronary artery distensibility and coronary area at mid-diastole in healthy adults or at end-systole and mid-diastole in CAD patients, although coronary artery distensibility correlated with end-systolic coronary area in healthy subjects (p=0.024). In a subgroup analysis, in healthy subjects (N=17) aortic distensibility (2.4 ± 1.6 mmHg<sup>-1</sup>\*10<sup>3</sup>) trended higher than that in CAD patients (N=4) (1.5 ± 0.4 mmHg<sup>-1</sup>\*10<sup>3</sup>), however, the difference was not statistically significant (p<0.22). We found no significant correlation between coronary artery and aortic distensibility in healthy adults or CAD patients (R<sup>2</sup>=0.0208; p=0.533) (Figure 3).

## DISCUSSION

We used 3.0 T MRI to non-invasively assess human coronary artery vessel wall distensibility and observed significant differences between healthy subjects and CAD patients. Our findings are similar to those from invasive IVUS studies for coronary artery distensibility (2,3) and to MRI measurements of aortic distensibility at 1.5 T (1). With the available data to date, we observe no significant correlation between coronary artery distensibility and aortic distensibility either in healthy adults or CAD patients. This methodology may support the characterization of vascular anatomy and function in healthy and diseased states, as well as the response to interventions in patients with, or at increased risk for, CAD.

**ACKNOWLEDGEMENTS** This work is supported by NIH grant R01-HL084186, HL61912 and by the Donald W. Reynolds Foundation.

**REFERENCES** 1. Lee JM et al. *Diab Vasc Dis Res* 2007;4:44-8.; 2. Nakatani S et al. *Circulation* 1995;91:2904-10.; 3. Jeremias A et al. *Basic Res Cardiol* 2001;96:506-12.; 4. Oliver JJ et al. *ATVB* 2003;23:554-66.

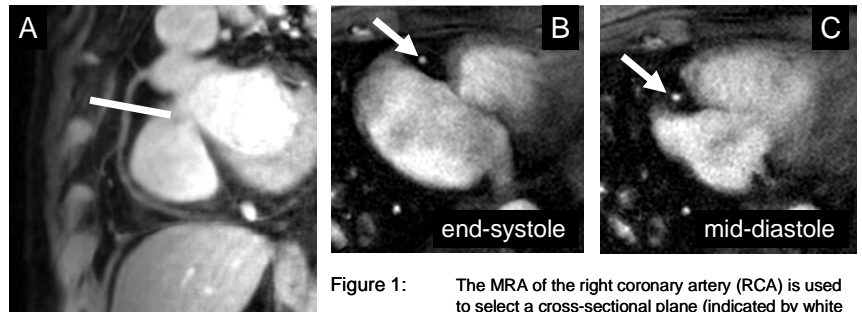


Figure 1: The MRA of the right coronary artery (RCA) is used to select a cross-sectional plane (indicated by white line). Images of the proximal RCA (white arrow) in end-systole (B) and at mid-diastole (C) in a CAD patient.

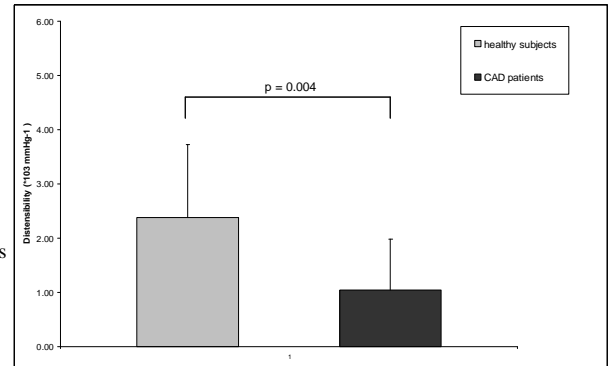


Figure 2: Distensibility measurements in healthy subjects and patients with CAD.

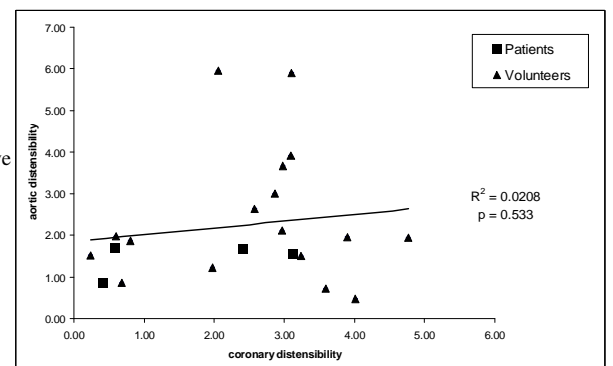


Figure 3: Correlation of aortic and coronary artery distensibility (in mmHg<sup>-1</sup>\*1000) in a subgroup of 17 healthy adults and 4 CAD patients.