

# Time-Resolved MR Angiography of the Distal Lower Extremities: Clinical Application, Vessel Diameters, and Contrast Dynamics

G. S. Sandhu<sup>1,2</sup>, R. P. Rezaee<sup>3</sup>, J. L. Duerk<sup>1,4</sup>, M. A. Griswold<sup>1,4</sup>, and V. Gulani<sup>1,2</sup>

<sup>1</sup>Department of Radiology, University Hospitals of Cleveland, Cleveland, Ohio, United States, <sup>2</sup>Case Center for Imaging Research, Case Western Reserve University, Cleveland, Ohio, United States, <sup>3</sup>Department of Otolaryngology-Head and Neck Surgery, University Hospitals of Cleveland, Cleveland, Ohio, United States, <sup>4</sup>Department of Biomedical Engineering, Case Western Reserve University, Cleveland, Ohio, United States

**Introduction:** Contrast enhanced MR angiography (ceMRA) is widely used for non-invasive screening and evaluation of vascular pathology. However, given that the data acquisition time from the volume of interest is long, only one or maximally two arterial phases can be acquired during a given exam. If the contrast agent bolus does not arrive during this period, or if dynamic arterial phase information is needed, ceMRA fails. Time resolved imaging with stochastic trajectories (TWIST) is a view sharing method for dynamic MRA in which k-space is divided into two areas, with the inner region of k-space sampled with twice the frequency of the outer region, half the outer region being sampled for each pass through the center of k-space. This allows time-resolved ceMRA where multiple volumes can be acquired throughout the arterial phase of enhancement [1]. A problematic region for MRA is the distal lower extremity, where time to bolus arrival is highly variable due to a patient's cardiac status or habitus, proximal vascular disease, and differential perfusion in the limbs. Imaging at a given time after injection results in missed boluses or late imaging and thus inefficient use of contrast, loss of scanner time, patient discomfort, and delay in pathological diagnosis. The distal lower extremity therefore is an ideal region for the application of the TWIST method for time resolved imaging. Here we present the application of TWIST for distal lower extremity angiography and perform additional analyses to investigate contrast dynamics of the lower legs.

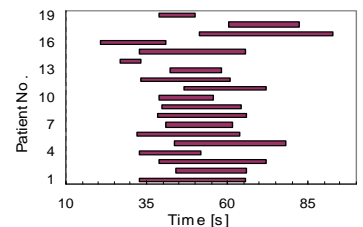
**Methods:** In this IRB approved study, 19 patients, mean age 65.9 yrs (27-83, M/F 14/5) underwent both a dynamic MRA exam at 3.0 T (Magnetom Verio, Siemens, Erlangen, Germany) with TWIST in the distal lower extremity and a traditional bolus-chase ceMRA 10 minutes later. Peripheral run-off and body coils were used for signal acquisition. The bolus-chase ceMRA exam was performed with a full dose (0.1 mmol/kg) and a TWIST angiogram of the distal lower extremity with a half-dose (0.05 mmol/kg) of Gadoversetamide (Optimark; Mallinckrodt Inc. St. Louis, MO, USA) respectively. TWIST images were acquired as described previously with a modified 3D Fast Low Angle Shot (FLASH; TR/TE 2.5/1.0 ms,  $\alpha$  22°, BW 1115, FOV 313×400×96mm<sup>3</sup>, MX 203×320×64, GRAPPA 2, 25 images, 5.1 s/ image) acquisition [1]. ceMRA was performed as an abdominal MRA and runoff, using T1-W FLASH (TR/TE 3.2/1.2 ms,  $\alpha$  25°, BW 700, FOV 350×400×96 mm<sup>3</sup>, MX 369×448×96). A review of the image data was performed and times for first appearance of contrast in the TWIST image and complete enhancement of the lower leg arteries in both legs were calculated from sub volume MIP projections reconstructed from TWIST source data. Axial MIP images (2 mm thick), reconstructed from the source images were used to measure diameters of anterior tibial (ATA), posterior tibial (PTA) and peroneal arteries at corresponding locations in ceMRA and TWIST images. Data from bilateral extremities were used (one patient had only one leg). Two patients moved during acquisition of TWIST images. In these patients, contrast times were analyzed from the raw data. However, arterial diameters were not measured due to difficulty in localizing corresponding points in TWIST and ceMRA locations. Arterial diameter measurements were also not performed in cases where venous contamination impeded proper visualization of individual arteries in ceMRA images. Means and standard deviations of time elapsed between the beginning of contrast injection and the first appearance of contrast in TWIST images (time A), contrast injection and complete enhancement of all the arteries (time B), first appearance of contrast in TWIST images and complete enhancement of all the major arteries are analyzed (time C). Statistical difference of apparent diameters of arteries in TWIST and ceMRA was analyzed using the paired t-test and a P-value of 0.05 was taken as reference for significance.

**Results and Discussion:** Figure 1 is a graphical representation of the individual times for contrast appearance and complete enhancement of arteries of all the patients. Mean and standard deviations of times A, B and C is 38.7±8.9 s, 63.2±13.8 s, and 24.5±8.7 s respectively. In one patient, values of time A, B and C were lower for the left leg by 26 s as compared to the right leg (Figure 2), and a diagnostic exam was made possible only by TWIST. Arterial diameters are shown in Table 1. Mean ATA diameter in TWIST images is significantly larger than that in ceMRA images (P value 0.02). Mean peroneal artery and PTA diameters are larger in TWIST images, and p-values of their difference (0.14 and 0.23 respectively) suggest a trend but do not reach significance. Values of A, B, and C for individual patients fall outside ±5 s of the mean in 58%, 52%, and 58% and outside ±10 s of the mean in 21%, 37% and 16% of patients, respectively. This variability in contrast arrival and arterial enhancement underscores the importance of TWIST for evaluation of the distal lower extremities. Without TWIST, early or late imaging could easily result in missing the contrast bolus or venous contamination. Larger apparent vessel diameters in TWIST could be due to larger voxel size and the view sharing technique employed. The observed diameter differences are less than 0.5 mm, however, and are of doubtful clinical significance. A possible weakness in our study is that the traditional MRA exam was performed after the TWIST study, and conceivably venous contamination could relate to the half-dose of contrast administered for the TWIST exam. However, we waited 10 minutes after the initial injection, and the venous contamination from the first study was found not to be a factor as the subtraction images eliminated this contamination effect. A weakness of TWIST is that it is a single station study and multiple contrast doses are needed for imaging at multiple stations. Finally, spatial resolution of images produced by TWIST is significantly lower than those of ceMRA. In our experience, a major strength of TWIST is that a small amount of contrast is needed for the exam. We used a half dose of Gd, and smaller doses may also yield clinically useful images. Also, due to the dynamic nature of the exam, there is virtually no chance of missing a contrast bolus with TWIST. Thus the number of call-back examinations due to venous contamination can be reduced to zero.

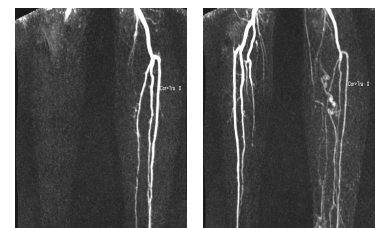**Conclusion:** This work demonstrates the clinical utility of time resolved angiography in form of TWIST in evaluating the distal lower extremity with a low contrast dose, and minimal loss in resolution.

**References:** 1. Vogt FM, et al. Proc. ISMRM 2008; 16: 2869.

**Acknowledgments:** This work was partially supported by Siemens Healthcare. VG is also supported in part by NIH/NCRR 1KL2RR024990.



**Fig 1:** Times for first appearance of contrast bolus and complete enhancement of lower leg arteries (marked by start and end of the bars respectively) in TWIST images of all the patients.



**Fig 2:** TWIST images of a patient with different times of complete enhancement of arteries of left (left image) and right (right image) leg. Arteries of right leg enhance 26 sec after that of left leg when significant venous contamination has already occurred in left leg. Signal from arteries of left leg is significantly lesser in the right image than the left image.

Artery	Diameter [mm]		P value
	TWIST	ceMRA	
ATA	4.6	4.2	0.02
PTA	4.4	4.2	0.23
Peroneal	4.5	4.3	0.14

**Table 1:** Mean arterial diameters in TWIST and ceMRA images and P-values of their difference showing statistical significance.