

Therapy response in glioblastoma multiforme evaluated with diffusion/perfusion MRI

B. R. Persson¹, E. Steffensen¹, M. Holmberg², and E-M. Larsson¹

¹Department of Radiology, Aalborg Hospital/Aarhus University Hospital, Aalborg, Denmark, ²Department of Oncology, Aalborg Hospital/Aarhus University Hospital, Aalborg, Denmark

Introduction: Dynamic susceptibility contrast perfusion MRI (DSCI) is increasingly used together with diffusion weighted imaging (DWI) in clinical investigation of patients with brain tumors. These two techniques may provide additional information to conventional gadolinium contrast enhanced T1 weighted imaging. Tumor size and relative cerebral blood volume (rCBV) are used for therapy monitoring. Non-invasive perfusion techniques for cerebral blood flow (CBF) calculations, such as arterial spin labeling (ASL) MRI, are emerging as alternative techniques for monitoring of brain tumors. Before implementing new techniques in clinical practice, it is important to investigate if CBF can replace CBV without affecting the diagnostic accuracy. Apparent diffusion coefficient (ADC) based on DWI can potentially also be used to validate response to therapy in brain tumors.

Purpose: To validate perfusion and diffusion weighted MRI in comparison with conventional contrast enhanced MRI for analysis of therapy response in patients with glioblastoma multiforme and to investigate if rCBF values can be used instead of rCBV values.

Material & Methods Patients: Retrospective study of patients with glioblastoma multiforme. Inclusion criteria: at least two perfusion investigations during the last 2 years (from October 2006 to October 2008). So far 11 patients (5 female, 6 male, mean age 55,4 years, range 43-66) with glioblastoma multiforme with in average 3,4 perfusion investigations (min. 2, max. 7, with 2 to 4 months between investigation) were re-evaluated. All patients have received radiation therapy and chemotherapy with temozolomide after operation/biopsy and chemotherapy with Cetuximab/Irinotecan/Bevacizumab at tumor progression.

MRI protocol: MRI was performed on 3T and 1.5T systems (Signa HDx, GE Healthcare) and includes: axial DWI, axial DSCI (GRE EPI, Gd-based contrast agent 0.1 mmol/kg) and axial T1 post-contrast imaging sequences.

Analysis: Tumor volumes were determined by manual drawing of the tumor border on axial T1 gadolinium enhanced images. Maximum enhancement on rCBV and rCBF maps (region of interest (ROI) size of about 0.2cm²) in tumor region was evaluated in term of the ratio to white matter (WM) and cerebellum. Care was taken to place ROIs at approximately the same position on ADC maps.

Results: The rCBF ratios tumor to normal appearing WM followed the volume response of the tumors during therapy (fig. 1). For all follow-up scans there were only 2 out of the 26 scans, where decrease in CBV was accompanied by increase in CBF. The correlation coefficient for ratios CBF and CBV in tumor to WM and to cerebellum was 0.68 and 0.77, respectively. For 6 patients decrease and increase in tumor size followed respectively by increase and decrease in ADC value (fig. 3). For the remaining patients the longitudinal ADC behaviour was unpredictable.

Conclusion: Both rCBV and rCBF ratios often followed the reduction of the tumor size and may provide additional information about tumor malignancy. rCBF data could probably be used for evaluation of therapy effects in glioblastoma multiforme where rCBV is not available, such as in ASL perfusion MRI. ADC inversely followed the tumor size during therapy in most cases, which is in agreement with previous studies.

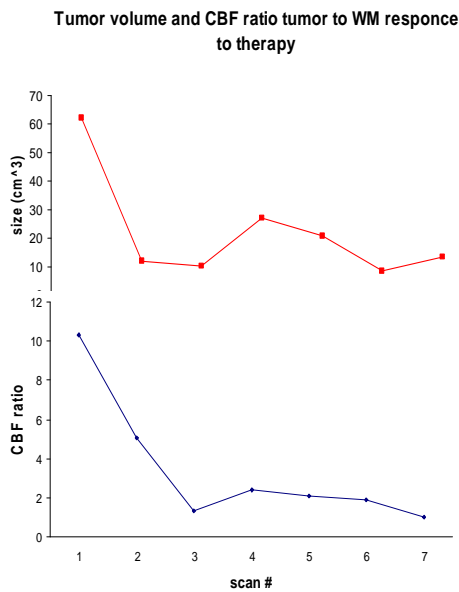


Figure 1. Comparison of the CBF ratio and tumor size during therapy in one of the patients with 7 perfusion MRI scans during therapy.

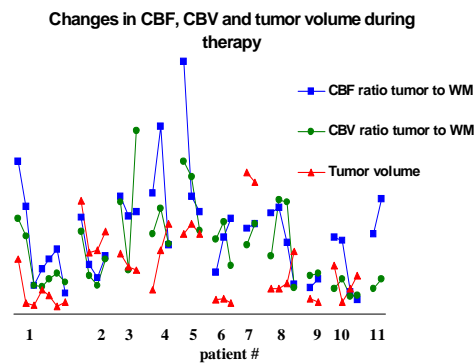


Figure 2. Longitudinal changes in CBF, CBV ratios and tumor volume for all patients during therapy.

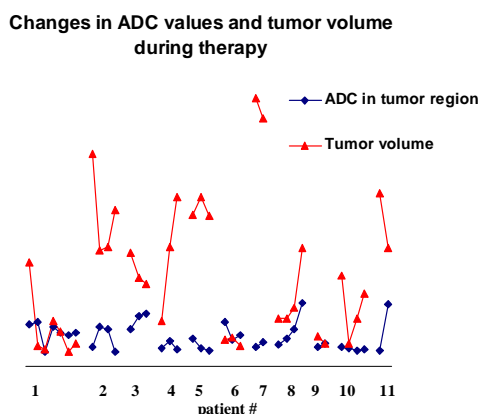


Figure 3. Longitudinal changes in ADC plotted together with changes in tumor volume for all patients during therapy.