

White matter damage in the vegetative and minimally conscious states: further insights from diffusion tensor imaging

V. Newcombe^{1,2}, M. Coleman^{2,3}, J. Cross⁴, J. Pickard^{2,5}, G. Williams², and D. Menon^{1,3}

¹Division of Anaesthesia, University of Cambridge, Cambridge, Cambridgeshire, United Kingdom, ²Wolfson Brain Imaging Centre, University of Cambridge, Cambridge, Cambridgeshire, United Kingdom, ³Cambridge Impaired Consciousness Research Group, ⁴Department of Radiology, Addenbrooke's Hospital, Cambridge, ⁵Academic Neurosurgery Unit, University of Cambridge

Introduction: The diagnoses of vegetative state (VS) and minimally conscious state (MCS) encompass a spectrum of patients who have emerged from coma to be awake, but show either no indication of awareness (VS), or intermittent, inconsistent responsiveness (MCS). These clinical outcomes are most commonly due to traumatic brain injury (TBI) and ischaemic/hypoxic injuries (IHI). Diffusion tensor imaging (DTI) could identify variations in white matter neuropathology between subjects and etiologies, and lead to greater diagnostic precision, refined prognostication, and better selection of patients for clinical trials.

Methods: 20 patients (15 TBI, 5 IHI) underwent MR imaging at a minimum of six months post injury using a 3 Tesla Siemens Magnetom Total Imaging Matrix (TIM) Trio system. Informed assent was obtained from next-of-kin in all cases. Ethical approval was obtained from the Local Research Ethics Committee. Thirty-two age matched controls underwent an identical imaging protocol which included a 3D T1 weighted structural sequence (MPRAGE), an auditory fMRI paradigm, and DTI. The DTI parameters were as follows; 12 non-collinear directions; 6 b values (0 to 1590 s/mm²); field of view: 100 x 100; 63 axial slices, 2mm slice thickness; TR = 6000ms; TE = 100ms; diffusion sensitizing duration 23.5ms (δ), with 60 ms separation (Δ) (leading edge to leading edge). Regions of interest were manually drawn using Analyze 7.0¹ in MNI125 space using Colin27² as a high resolution, high signal-to-noise template, and included the pons, ventral midbrain, dorsal midbrain, and corpus callosum (genu and splenium). Each subject's own MPRAGE was segmented to create a whole brain white matter mask (WBWM) using FMRIB's Automated Segmentation Tool (FAST).³ FA, ADC and eigenvalue maps were created using FDT in FSL.⁴ The diffusion weighted data were normalized using the vtkCISG normalized mutual information algorithm, using a two step approach.⁵ The b=0 image was subsequently coregistered to the subject's own MPRAGE. The transformation matrix normalizing the MPRAGE was then applied to the b=0 image. All coregistered images were visually inspected to ensure that ROIs corresponded to the regions specified. Mean FA for the different ROIs were calculated. As the data was nonparametric the Mann-Whitney U Test was used to analyze the data. A qualitative mapping of white matter loss was undertaken using "Global" streamline tractography.⁶

Results: FA values were broadly similar for the two etiologies in the supratentorial ROIs, but the brainstem exhibited more changes in the TBI group (Fig 1). These regional variations in white matter injury were confirmed by visual inspection of global tractography images (Fig 2).

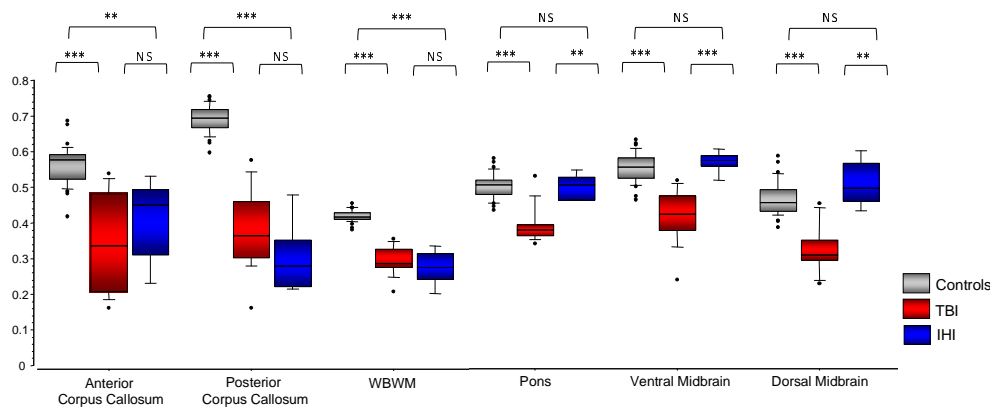


Figure 1: Fractional anisotropy values for the ROIs studied with results of the Mann-Whitney U test shown. The central lines in the boxes denote the median values, the upper and lower edges the 75th and 25th percentiles, the error bars the 90th and 10th percentiles and the closed circles the data outside these percentiles. ** p < 0.01; *** p < 0.001; NS, non-significant.

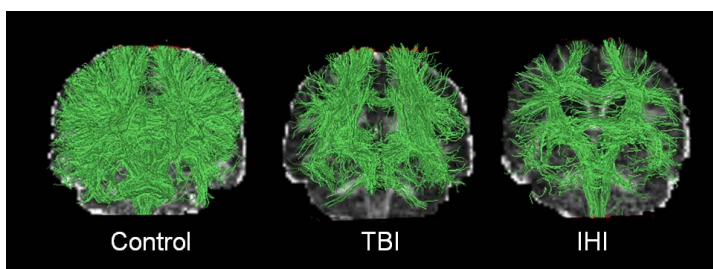


Figure 2: "Global" streamline tractography⁶ with representative examples from the control, TBI and IHI groups overlaid on their FA maps. It can clearly be seen that the paths able to be successfully tracked are fewer in the patients. Also apparent is the perseveration of the brainstem white matter tracts in IHI compared to TBI. For ease of visualization, tracts with lengths less than 3cm are not shown.

Discussion: There was evidence of marked, and broadly similar, abnormalities in the supratentorial grey and white matter compartments in both aetiologies. In contrast discordant findings were found in the infratentorial compartment, with DTI abnormalities in the brainstem confined to the TBI group.

References:

- Analyze. <http://www.mayo.edu/bir/>
- Holmes et al, *J Comp Assist Tomogr* 1998;**22**(2):324-33.
- Zhang et al, *IEEE Trans Med Imaging* 2001;**20**(1):45-57.
- FSL. www.fmrib.ox.ac.uk/fsl/
- vtkCISG. www.image-registration.com
- Sherbondy et al, *IEEE Trans Vis Comput Graph* 2005;**11**(4):419-30