


MRI evidence that gadolinium-enhancing lesions seen twelve weeks after commencing rituximab treatment are associated with lower blood-brain-barrier disruption than those seen prior to treatment in patients with relapsing-remitting multiple sclerosis

Z. Caramanos^{1,2}, I. Leppert¹, S. Narayanan^{1,2}, G. B. Pike¹, and D. L. Arnold^{1,2}

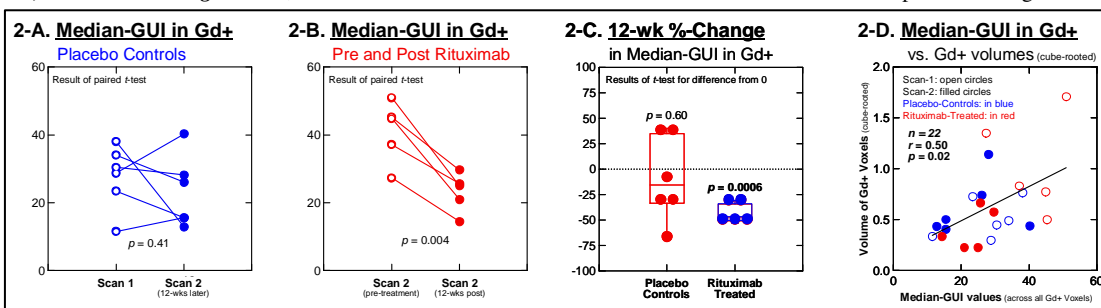
¹McConnell Brain Imaging Centre, Montreal Neurological Institute, McGill University, Montreal, Quebec, Canada, ²NeuroRx Research, Montreal, Quebec, Canada

INTRODUCTION The investigation of blood-brain-barrier (BBB) disruption in patients with multiple sclerosis (MS) has been limited primarily to the qualitative analysis of enhancement that is seen following the injection of chelated Gadolinium (Gd), with lesions typically being categorized as either Gd-enhancing (Gd+) or not. For example, in a recent phase-II, double-blinded, 48-week-long, randomized clinical trial of 104 patients with relapsing-remitting (RR) MS (Hauser *et al.*, *N Engl J Med.* 2008;358:676-88), patients treated with rituximab ($n=69$), a monoclonal antibody that selectively targets and depletes CD20+ B lymphocytes, had significant reductions in both their mean number and volume of Gd+ lesions relative to placebo-control patients ($n=35$). A more quantitative approach examining changes in T1-weighted signal intensity following Gd injection has been shown to enable detection of subtle BBB disruption and leakage in patients with MS (Silver *et al.*, *Mult Scler* 2001;7:75-82); such an approach could allow for a more complete description of the degree of such disruptions in patients with MS, as well as of how these disruptions might be affected by treatment. The present study examined the effect of rituximab on BBB-disruption within the Gd+ lesions of patients with MS; importantly, this was done using a semi-quantitative Gd-uptake index (GUI) that is easily obtained in a clinical context (Cao *et al.*, *J Clin Oncol* 2005;23:4127-36).

METHODS *Subjects*: BBB disruption was quantified for: (i) the five rituximab-treated patients from the 2008 Hauser *et al.* clinical trial that had at least one Gd+ lesion immediately prior to treatment and at least one Gd+ lesion twelve weeks afterwards, and (ii) the six placebo-control patients from that study that had at least one Gd+ lesion on each of two scans obtained twelve weeks apart. Rituximab-treated patients had each received 1000 mg of rituximab intravenously at Day-1 and at Day-15 of the study. *Image acquisition*: For each patient, a T1-weighted MRI scan (3D gradient-recalled echo, TR = 30 ms, TE = 8-10 ms, 30° flip angle, 256 x 256 matrix, 250 mm FOV) was acquired at each timepoint, both before and ten minutes after Gd injection. *Measure of BBB disruption*: GUI values were generated for each of the resulting pre- and post-Gd scan-pairs using a method similar to that of Cao *et al.* (*J Clin Oncol* 2005;23:4127-36). Essentially, the natural logarithm of the ratio of post- to pre-injection images is used as a measure of Gd-uptake. The resulting GUI values reflect the change in spin-lattice relaxation (*i.e.*, T1) due to the injection of Gd, with positive GUI values that are greater than those seen in the background noise indicating BBB leakage. *Image post-processing*: In order to correct for differences in receiver gain, each post-treatment image was normalized to the corresponding pre-treatment image. In-house software was used to: (i) register the pre- and post-treatment images; and then (ii) normalize the images using a global-scaling, root-mean-square approach in order to minimize the differences in voxel intensity between the source and target images. The resulting GUI maps were: (i) scaled by a factor of 100 in order to avoid small fractional values; and (ii) clamped to have values from -50 to 150 in order to not overwhelm the dynamic range with extremely large ratios in the background noise. *Gd+-lesion segmentation*: As part of the original 2008 Hauser *et al.* clinical trial, Gd+ lesion-voxels were identified in a blinded fashion by the consensus of two staff members at a central MRI reading center (NeuroRx Research, Montreal, Canada). Median GUI-values were calculated across the Gd+-lesion voxels in each patient's scans. **Figure 1** shows, for one of the rituximab-treated patient's pre-treatment data: (I-A) the GUI map, (I-B) the Gd+ masks, and (I-C) their superimposition.



RESULTS As shown in **Figure 2-A**, there was no statistically-significant 12-week change in the placebo-control patients' mean degree of within-Gd+-voxel BBB disruption (as assessed by the median GUI-value calculated across each of the patient's Gd+ voxels) [Scan-1: mean (standard deviation, SD) median-GUI-values = 27.7 (9.3); Scan-2: 23.1 (10.5); paired *t*-test of mean difference: $t = 0.91$, $df = 4$, $p = 0.41$]. On the other hand, as shown in **Figure 2-B**, all of the rituximab-treated patients showed evidence of decreased BBB disruption in their Gd+ lesion voxels twelve weeks after the commencement of treatment [Scan-1: 41.1 (9.1); Scan-2: 23.1 (5.8); paired *t*-test: $t = 6.12$, $df = 4$, $p = 0.004$]. As shown in **Figure 2-C**, these findings were reflected in a mean (SD) 12-week decrease of 43.4% (10.0%) in the median-GUI-values of the rituximab-treated patients (one-sample *t*-test of difference from 0: $t = -9.65$, 4 df , $p = 0.0006$). However, the mean 12-week percent-change that was seen in the placebo-control patients was not statistically different from 0 (-9.4% (41.0%); one-sample *t*-test: $t = -0.56$, 5 df , $p = 0.60$). As shown in **Figure 2-D**, individuals' median within-Gd+-lesion-voxel levels of BBB disruption were significantly related to the total volume of their Gd+-lesion voxels [Pearson Product-Moment correlation: $r = 0.50$, $p = 0.02$]. Importantly, after adjusting for sample size, the subjects' total Gd+-lesion-voxel volumes accounted for only 21.7% of the variance in their within-Gd+-voxel median-GUI values. (NB: Total Gd+-lesion volumes were cube-rooted in order to correct for their skewed nature prior to parametric statistical analysis.)



DISCUSSION Building on previous findings that treatment with rituximab results in reduced Gd+-lesion counts and volumes in patients with RR-MS (Hauser *et al.*, *N Engl J Med.* 2008;358:676-88), in the present study we found evidence to suggest that those Gd+-lesion voxels that are seen twelve weeks after the start of such treatment are associated with significantly-lower BBB disruption than those that were seen prior to such treatment. Our results suggest that a continuous classification of BBB disruption in patients with MS may reveal treatment-related changes that are not detected by the conventional binary classification of lesions as being either Gd+ or not. Furthermore, our results suggest that the relatively-easy-to-quantify measure of BBB disruption that we used in the present study can provide additional information that is independent of that which is provided by the typical measure of Gd+-lesion volume.

Supported by Biogen Idec and Genentech