

VASCULAR MODULATION OF SCI: A LONGITUDINAL MRI STUDY

L. Sundberg¹, J. Herrera¹, and P. Narayana¹

¹Diagnostic and Interventional Imaging, The University of Texas Medical School, Houston, TX, United States

Introduction: Angiogenesis, an essential component of wound repair, is known to occur in response to spinal cord injury (SCI), yet its role in neurological recovery is controversial. Angiogenesis may be beneficial in the early stages of SCI as it may improve tissue perfusion and allow for critical nutrients to be delivered to the spared tissue; however, in the chronic phase of injury it may be detrimental due to the permeability of the new vessels resulting in an inflammatory reaction to blood-borne materials that leak into the spinal cord tissue. The purpose of these studies was to modulate angiogenic activity, via direct epicenter administration of either VEGF, a potent pro-angiogenic factor, or anti-VEGF to suppress angiogenic activity, and investigate the outcome in experimental SCI. Lesion volume was determined by high resolution anatomical MRI to evaluate the evolution of the lesion over a period of 56 days and the data was correlated with a variety of neurobehavioral assays such as the Beattie, Basso, Bresnahan (BBB) open field locomotion, inclined plane, grid walk, and von Frey testing.

Methods: A total of 60 adult male Sprague-Dawley rats, each weighing between 300 to 350 g, were used in these studies. The rats were assigned to one of four groups: SCI treated with VEGF (n=17), SCI treated with anti-VEGF (n=15), SCI treated with saline (n=16), or laminectomy only (n=12). All animals underwent surgery under isoflurane anesthesia in which they received a laminectomy; animals in the injured groups received a moderately severe contusion at level T7 using the Infinite Horizon impactor. The assigned treatment was administered at the time of surgery via direct injection into the site of contusion. An 11x35 mm implanted RF coil was positioned above the site of injury and was inductively coupled to an external coil for improved signal-to-noise ratio. Prior to each MR session, a battery of neurobehavioral assays was performed to assess animals' neurobehavioral and neurosensory condition. MRI scans were performed on days 7, 14, 28, 42, and 56 post-injury using a Bruker 7T scanner. Multi-slice RARE images were acquired with a rare factor of 4 and TE₁/TE₂/TR of 21.2/63.6/3150 ms. A total of 35 contiguous and interleaved 1 mm thick axial images with a square FOV of 2.62 cm and 256 x 256 image matrix were acquired. The RARE images were inspected for lesions; regions of interest, which included areas of hyper- and hypointensities, were selected using the Image-Pro Plus 5.1 software (Media Cybernetics, Inc., Silver Spring, MD) and lesion volumes were quantified. Differences in the hyper- and hypointense lesion volumes as well as behavior measures for all treatment groups were evaluated using Wilcoxin rank-sum test and multiple comparisons were corrected for using the Bonferroni correction for alpha. Generalized estimating equation (GEE) analysis was used to evaluate the temporal correlations within each group.

Results and Discussions: In the acute phase of injury, hyperintense lesions correspond to edema and hypointense lesions correspond to hemorrhage, while in the chronic stages of injury they are associated with demyelination and necrosis, respectively (1). The temporal changes in the hypo- and hyperintense lesions are summarized in Figure 1. In all injured groups, the hyperintense injury peaked 7 days post-injury and steadily decreased in volume, indicating the resolution of edema over time. There was no treatment effect on the hyperintense lesion volume. The hypointense lesion volume was decreased in the VEGF-treated animals through day 28, but by day 42 there were no significant differences between the injured groups. Based on these results, it appears that delivery of VEGF at the time of injury results in less hemorrhage and necrosis for the first four weeks of injury, but the beneficial effect of VEGF treatment is not sustained. In addition, neurobehavioral assays indicate that VEGF treatment may lessen the development of neuropathic pain after injury, as indicated by Von Frey filament testing, possibly because of the initial increase in spared tissue. The anti-VEGF treated animals had more footfalls on the grid walk test and lower thresholds to the Von Frey stimulus, though these differences were not statistically significant. This indicates that the anti-VEGF treated animals may experience more damage to specific white matter tracts and develop mechanical allodynia following SCI. Correlations between both hypo- and hyperintense lesion volumes and neurobehavioral tests were observed, providing information on the condition of specific white matter tracts following injury. Based on these results it appears that acute VEGF treatment of SCI is beneficial and results in less hemorrhage and necrosis, though the benefits of VEGF treatment are not permanent. It is possible that sustained delivery of VEGF may result in improved and more robust outcome in SCI. Additionally, our studies suggest that removal of the endogenous VEGF by administration of anti-VEGF is detrimental, implying that acute angiogenic response is a favorable process following SCI.

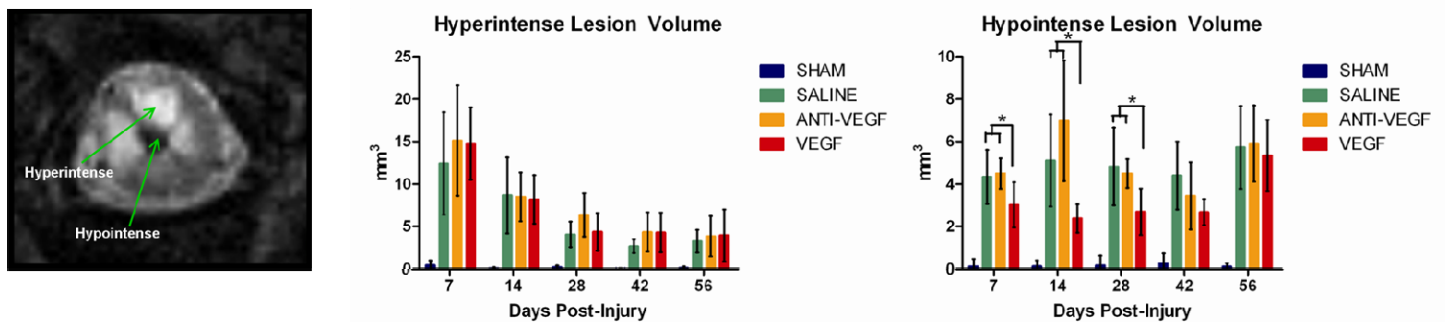


Figure 1: Hyper- and hypointense lesion volumes plotted with respect to time post-injury. Hyperintense lesions correspond to edema and demyelination, while hypointense lesions correspond to hemorrhage and necrosis.

Conclusions: MRI lesion volumes were calculated for hypo- and hyperintense injuries to determine the effect of pro-angiogenic VEGF treatment in the acute phase of SCI. These studies indicate that treatment of SCI with VEGF is beneficial and results in diminished hypointense lesion volume up to four weeks post-SCI. Treatment with VEGF may also improve neurobehavioral and neurosensory outcome after injury due to increased sparing of white matter tracts.

Acknowledgements: Funded by NIH Grant # R01 NS 30821.

1. Weirich SD, Cotler HB, Narayana PH, Hazle JD, Jackson EF, Coupe KJ, McDonald CL, Langford LA, Harris JH Jr. Histopathologic correlation of magnetic resonance imaging signal patterns in a spinal cord injury model. Spine 1990 Jul;15(7):630-8